Urticaria and Angioedema 18

Clive E.H. Grattan, Emek Kocatürk and Sarbjit S. Saini

Synonyms: ■ Wheals – hives, nettle rash ■ Angioedema – Quincke edema, angioneurotic edema

Key features

- Urticaria is characterized by transient skin or mucosal swellings due to plasma leakage. Superficial dermal swellings are wheals, and deep swellings of the skin or mucosa are termed angioedema. Wheals (hives) are characteristically pruritic and pink or pale in the center, whereas angioedema is often painful, less well-defined, and shows no color change
- There are several recognizable clinical patterns of urticaria and different causes. The latter include allergy, autoimmunity, drugs, dietary pseudoallergens, and infections. Many cases of spontaneous urticaria remain unexplained ("idiopathic") even after an extensive evaluation; they may also be multifactorial
- C1 esterase inhibitor deficiency and angiotensin-converting enzyme (ACE) inhibitors need to be considered as causes of recurrent angioedema without wheals
- Diagnosis is based primarily on the history and clinical examination. Determination of the etiology or triggers, as well as exclusion of other diagnoses, may require further investigations, including blood tests, physical and dietary challenges, skin tests, and skin biopsy
- Urticaria is a common disorder that may cause considerable distress and last for years, but the symptoms can usually be alleviated by appropriate management

INTRODUCTION

Urticaria is a common reason for patients to present to primary care practitioners, emergency rooms, dermatologists, and allergists. It is characterized by the rapidity of its fluctuation. As a rule, individual wheals last no more than 24 hours, but the entire affliction usually lasts much longer. With nearly all clinical patterns of urticaria, wheals may be accompanied by angioedema, but the occurrence of isolated angioedema (without wheals) is of special significance because some of these patients will have a deficiency of C1 esterase inhibitor (C1 inh). The latter is due to bradykinin formation rather than release of mast cell mediators. C1 inh deficiency is a rare disorder that is often inherited and because it can prove fatal without treatment must be considered in any patient with isolated angioedema. Urticarial vasculitis is an important disorder to exclude in patients with chronic urticaria. It is a systemic disease defined by damage to small blood vessels rather than transient vasodilation and vascular permeability (see Ch. 24). Urticarial vasculitis sometimes presents with wheals or angioedema that, without confirming a duration of more than 24 hours (by serial examination of marked lesions) and a lesional skin biopsy, can be indistinguishable from chronic spontaneous urticaria (CSU). While urticaria rarely progresses to anaphylaxis, wheals are often a feature of that condition. Good management of urticaria depends on a thorough understanding of etiologies, triggers, and aggravating factors, in addition to the most appropriate drug therapies.

Definition of Urticaria

Urticaria is often used as a descriptive term for recurrent whealing of the skin, with angioedema being viewed as a physical sign. However, there is increasing acceptance that the term "urticaria" also defines an entity that may be acute or chronic. Thus, when viewed as a disease, urticaria may present with wheals, angioedema, or both.

Wheals are pruritic, pink or pale swellings of the superficial dermis that have an initial erythematous flare around them (Fig. 18.1). Lesions may be a few millimeters in diameter or as large as a hand, and the number can vary from a few to numerous. The hallmark of wheals is that, by definition, *individual* lesions come and go rapidly, generally within 24 hours. However, larger coalescing wheals may take longer to resolve.

Angioedema swellings occur deeper in the dermis and in the subcutaneous or submucosal tissue. They may also affect the oropharynx and rarely the bowel in hereditary angioedema. The areas of involvement tend to be normal or faint pink in color, painful rather than pruritic, larger, and less well-defined than wheals, and they often last for 2 to 3 days (Fig. 18.2).

EPIDEMIOLOGY

Depending on the age range and method of sampling, estimates of the lifetime prevalence of acute and chronic urticaria in the general population range from 8% to 22%[1]. In a recent meta-analysis, chronic urticaria had overall lifetime and point prevalence rates of 1.4% and 0.7%, respectively[2]. The prevalence of specific subtypes of chronic urticaria, e.g. the inducible urticarias, is lower[3].

Urticaria is a worldwide disease and may present at any age, with the peak incidence dependent upon etiology. The proportion of cases due to different etiologic agents is likely related to the frequency of environmental exposures, such as infections and allergens, in different countries, but estimates of this are not available. It is also often difficult to prove a cause and effect, and so an underlying condition may be inappropriately "blamed" for causing urticaria. Overall, urticaria is more common in women, with a female : male ratio of ~2 : 1 for CSU, but the ratio varies with the different physical urticarias. For example, women outnumber men in dermographism and cold urticaria, but more men develop delayed pressure urticaria. Hereditary angioedema has an autosomal dominant inheritance pattern and occurs in ~1 in 50 000 individuals, with a range that varies from 1 in 20 000 to 1 in 60 000.

PATHOGENESIS

The Mast Cell

Distribution and diversity

The mast cell is the primary effector cell of urticaria. Mast cells are widely distributed throughout the body but vary in their phenotype and response to stimulation. This may explain why systemic features, such as those seen in anaphylaxis, do not accompany the activation of cutaneous mast cells in urticaria. The majority of mast cells in the skin and intestinal submucosa contain the neutral proteases tryptase and chymase (MC_{TC}), whereas those in the bowel mucosa, alveolar wall, and nasal mucosa contain only tryptase (MC_T). Both types, however, express high-affinity IgE receptors (FcεRI) and are therefore capable of participating in IgE-dependent allergic reactions[4]. There is conflicting evidence on the number of cutaneous mast cells in chronic urticaria, but there is agreement that they may be more likely to degranulate in response to certain stimuli, such as intradermal codeine injection, and in this sense may be in general more "releasable". Little is known about the beneficial effects of mast cells, but there is evidence that they are involved in the innate immune response to infection, wound healing, and the neuroendocrine system. They have also been shown to help initiate the extracellular matrix formation and angiogenesis required for neurofibroma development.

Downloaded for Anonymous User (n/a) at Egyptian Knowledge Bank from ClinicalKey.com by Elsevier on March 10, 2024. For personal use only. No other uses without permission. Copyright ©2024. Elsevier Inc. All rights reserved.

Fig. 18.1 Wheals. A, B Wheals can vary in size from small to large as well as be annular, but they still retain the classic central pallor and erythematous flare. **C** Occasionally, more uniform edematous plaques are seen.

Fig. 18.2 Angioedema. The swelling is deeper than wheals and may affect mucosal surfaces. Note the swelling of the lips and periorbital region and the lack of erythema.

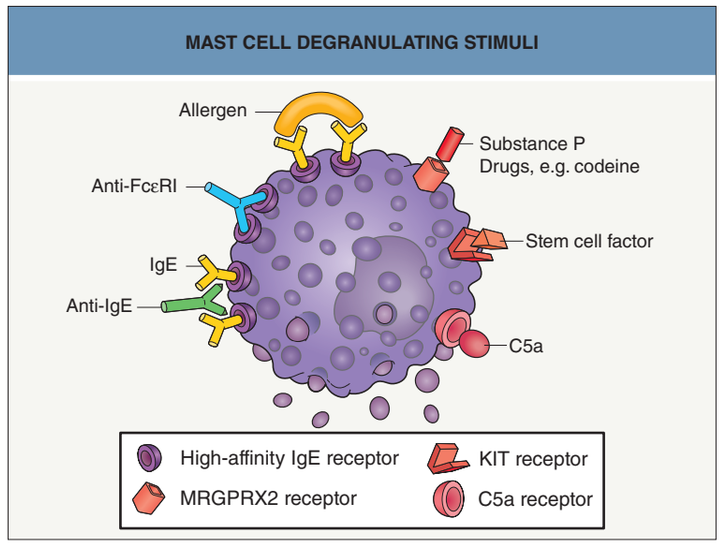

Fig. 18.3 Mast cell degranulating stimuli. Both immunologic and non-immunologic stimuli can lead to release of mediators. Substance P also binds to neurokinin 1 receptor; stem cell factor is also known as KIT ligand. MRGPRX2, MAS-related G-protein coupled receptor X2.

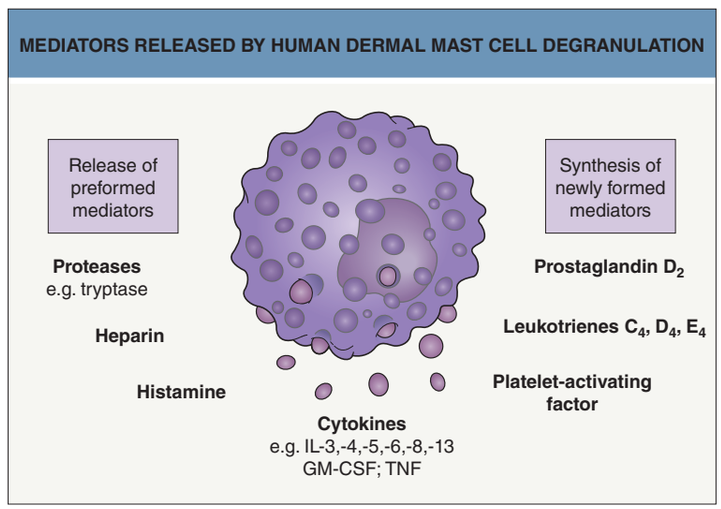

Fig. 18.4 Mediators released by human dermal mast cell degranulation. Both preformed and newly synthesized proinflammatory mediators are released from mast cells.

Degranulating stimuli

Cross-linking of two or more adjacent FcεRI on the mast cell membrane will initiate a chain of calcium- and energy-dependent steps leading to fusion of storage granules with the cell membrane and externalization of their contents. This is known as degranulation. Classic immediate hypersensitivity reactions involve binding of receptor-bound specific IgE by allergen. There are also several recognized immunologic degranulating stimuli that act through the IgE receptor, such as IgG anti-IgE and anti-FcεRI antibodies (Fig. 18.3).

Autoantibodies against FcεRI (IgG > IgM, IgA) are associated with disease markers of CSU[5], but the degree to which they mediate release of histamine from mast cells or basophils *in vitro* can vary. In addition, because anti-IgE and anti-FcεRI autoantibodies have been identified by immunoassays (but not functional assays) in patients with other diseases such as systemic lupus erythematosus[6] and occasionally in healthy controls, the role of autoantibodies in the pathogenesis of urticaria has been debated. Stimuli that can lead to mast cell degranulation independent of FcεRI activation include C5a, stem cell factor, and agents that bind MRGPRX2 (MAS-related G-protein coupled receptor X2; see Fig. 18.3); the latter include substance P and drugs such as opioids[7,8].

Proinflammatory mediators

Mast cell granules contain preformed mediators of inflammation, the most important of which is histamine (Fig. 18.4). A wide range of cytokines has been identified in human mast cells from different tissues, including tumor necrosis factor (TNF), interleukins (IL)-3, -5, -6, -8, and -13, and granulocyte–macrophage colony-stimulating factor (GM-CSF). Synthesis and secretion are upregulated following FcεRI stimulation. TNF is expressed constitutively in resting human cutaneous mast cells. Prostaglandins and leukotrienes are synthesized from arachidonic acid derived from cell membrane phospholipids. The

Downloaded for Anonymous User (n/a) at Egyptian Knowledge Bank from ClinicalKey.com by Elsevier on March 10, 2024. For personal use only. No other uses without permission. Copyright ©2024. Elsevier Inc. All rights reserved.

most important *proinflammatory* eicosanoids are prostaglandin (PG) D_2 and the leukotrienes (LT) C_4, D_4, and E_4 (slow releasing substance of anaphylaxis). PGE_2 has inhibitory effects on immunologic mast cell degranulation and may therefore have a protective role in urticaria. Increased levels of TNF, IL-1β, -6, -10, -12p70, -13, and B cell activating factor (BAFF) have been detected in the sera of urticaria patients[9].

Blood Vessels

Histamine and other proinflammatory mediators released upon degranulation bind receptors on postcapillary venules in the skin, leading to vasodilation and increased permeability to large plasma proteins, including albumin and immunoglobulins. Furthermore, histamine, TNF, and IL-8 upregulate the expression of adhesion molecules on endothelial cells, thereby promoting the migration of circulating inflammatory cells including eosinophils, basophils, neutrophils, and Th0 cells from the blood into the urticarial lesion[10].

Blood

Autoantibodies

Based upon *in vitro* assays, functional IgG autoantibodies that release histamine (and other mediators) from mast cells and basophils have been detected in the serum of 30%–50% of patients with CSU[11]. The *majority* of these autoantibodies bind the extracellular *α subunit of FcεRI*. Those recognizing the α_2 domain compete with IgE for the binding site, whereas non-competitive autoantibodies directed against the terminal α_1 domain are able to bind the receptor in the presence of IgE (Fig. 18.5). Increased serum levels of IgM anti-FcεRIα autoantibodies have also been found in patients with CSU and have been linked to features of autoimmune CSU[5]. Approximately 10% of chronic urticaria sera contain functional autoantibodies directed against the *Fc portion of IgE itself* (see Fig. 18.3). Binding of the autoantibodies to mast cells may initiate complement activation with the generation of C5a anaphylatoxin, which in turn facilitates or augments degranulation[12].

Circulating IgE autoantibodies directed against a range of autoantigens such as thyroid peroxidase (TPO), thyroglobulin, tissue factor, and IL-24 have been detected in patients with CSU[13–16]. However, healthy individuals and patients with disorders such as atopic dermatitis also have these IgE autoantibodies[17]. In patients with CSU and IgE anti-TPO antibodies, skin testing with recombinant TPO can elicit a wheal and flare reaction, indicating potential functionality, but it is still unclear as to why such patients develop only local wheals rather than systemic anaphylaxis[18].

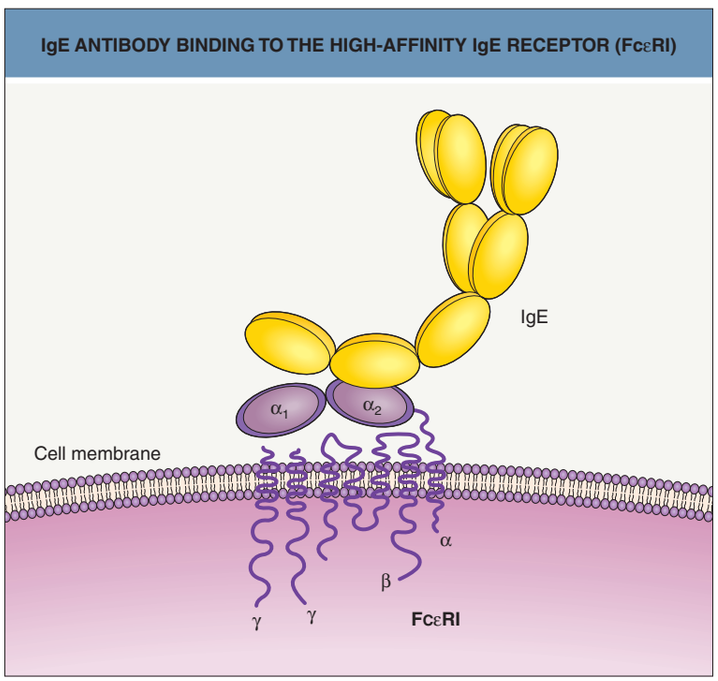

Fig. 18.5 IgE antibody binding to the extracellular α subunit of the high-affinity IgE receptor (FcεRI). Histamine-releasing autoantibodies directed against the terminal α_1 domain are able to bind the receptor in the presence of IgE and are therefore non-competitive, whereas those recognizing the α_2 domain compete with IgE for the binding site.

Other mast cell activating factors may also exist in urticaria sera, e.g. a non-IgG "mast cell-specific factor" has been described, although its identity remains unknown[19]. There is currently no evidence that characterized cytokines cause mast cell degranulation in urticaria. Evidence from small series of CSU patients treated with plasmapheresis[20] or cyclosporine[21] indicates that functional autoantibody levels correspond to disease severity.

Leukocytes

The importance of peripheral blood leukocytes in the pathogenesis of urticaria is becoming clearer. In general, blood ***basophils*** from CSU patients are less responsive *in vitro* to anti-IgE antibodies as an immunologic stimulus, possibly through desensitization, and these cells are reduced in number[22]. CSU patients can be further classified into responders and non-responders based upon the release of histamine by their basophils in response to anti-IgE antibodies or the flow cytometry-based basophil activation test (BAT). This basophil functional phenotype appears to remain stable during the course of the active illness, but then, during disease remission, the basophils become more responsive to anti-IgE antibodies[23]. Expression of the negative regulator SHIP (*s*rc *h*omology 2-containing *i*nositol *p*hosphatase) is increased in the basophils from anti-IgE non-responders[24], although the significance of this to the pathogenesis of chronic urticaria is unknown.

Evidence has emerged that basophils are recruited into urticaria wheals[25] and may sustain the inflammatory response by releasing histamine and other mediators, analogous to the delayed phase of immediate hypersensitivity reactions. A correlation between disease severity and the degree of reduction in circulating basophil counts has been observed[26]. This basopenia can normalize following successful treatment with omalizumab, providing support for the role of basophil migration into lesional skin during periods of disease activity[27].

In addition to basopenia, circulating eosinopenia may be present in those CSU patients who have greater disease activity and a lack of response to H1 antihistamines[28]. ***Eosinophils*** can contribute to the persistence of wheals by generating LTC_4, LTD_4, and LTE_4 and by releasing toxic granule proteins, including major basic protein (MBP); the latter can induce release of histamine from basophils and trigger mast cells via MRGPRX2[8]. Interactions between eosinophils and mast cells also include expression of tissue factor by eosinophils which then leads to activation of mast cells via protease activated receptors (PARs).

While ***lymphocyte*** numbers are normal in the peripheral blood of CSU patients, these cells are often present in biopsy specimens from spontaneous wheals. In one study, ~50% of the cells in the perivascular cellular infiltrates were T cells and ~20% were monocytes. Additional investigations in CSU patients noted the dermal infiltration of $CD4^+$ helper T cells, the majority of which co-expressed HLA-DR antigen; T cell activation in the peripheral blood as well as lesional and nonlesional skin; and increased expression of Th2-initiating cytokines in lesional skin[29]. Lastly, autoreactive $CD4^+$ T cells specific for FcεRIα were detected in the peripheral blood of patients with CSU[30].

Nerves

Substance P and other neuropeptides release histamine from mast cells *in vitro* and can induce a wheal and flare reaction in human skin when injected intradermally. Vasoactive intestinal polypeptide (VIP) caused a greater wheal reaction in those with chronic urticaria than did other skin-tested neuropeptides, but the relevance of this to urticaria is still uncertain. Elevated levels of brain-derived neurotrophic factor, β-endorphin, and substance P have been detected in patients with chronic urticaria[31–33]. Because several of these neuropeptides can bind MRGPRX2 on mast cells[34], the roles of neuro-immuno-cutaneous factors and neurotransmission in chronic urticaria require further clarification.

Mechanisms of Urticaria Formation

Mast cell-dependent urticaria

Potential mechanisms for mast cell-dependent urticaria are included in Table 18.1. Cross-linking of the Fab portion of specific IgE on mast

Downloaded for Anonymous User (n/a) at Egyptian Knowledge Bank from ClinicalKey.com by Elsevier on March 10, 2024. For personal use only. No other uses without permission. Copyright ©2024. Elsevier Inc. All rights reserved.

ETIOLOGIES AND PATHOMECHANISMS OF WHEALS AND/OR ANGIOEDEMA
Idiopathic
Immunologic
• Autoimmune (autoantibodies against FcεRI or IgE) • IgE-dependent (allergic) • Immune complex (vasculitic) • Kinin- and complement-dependent (C1 esterase inhibitor deficiency)
Non-immunologic
• Direct mast cell-releasing agents (e.g. opioids) • Vasoactive stimuli (e.g. nettle stings) • Aspirin, other nonsteroidal anti-inflammatory drugs, dietary pseudoallergens • Angiotensin-converting enzyme inhibitors

Table 18.1 Etiologies and pathomechanisms of wheals and/or angioedema. It is often difficult to know the exact pathogenesis of individual cases of urticaria, and many cases remain idiopathic after evaluation.

cells by percutaneous or circulating allergen undoubtedly accounts for some cases of acute or episodic urticaria, especially in children (see Fig. 18.3), but this is probably never the cause of adult chronic continuous urticaria. Examples of the former would be contact urticaria from natural rubber latex and acute urticaria from foods, including nuts, fish, and fruit. However, the majority of acute urticaria cases do not relate to allergen exposure.

IgE has been implicated in the pathogenesis of symptomatic dermographism, cold urticaria, and solar urticaria, but the mechanism by which it renders skin mast cells more sensitive to physical stimulation is not certain. It is proposed that the physical stimulus in these patients induces a neoantigen that reacts with specific IgE antibody bound to mast cells. An additional mechanism, such as neuropeptide release, could initiate or potentiate mast cell activation (see above). Using electron microscopy, localized platelet clumping has been demonstrated in cold urticaria, and the release of platelet mediators, including platelet-activating factor (PAF) and platelet factor 4/CXCL4, could contribute to wheal formation. A mutation in *F12*, which encodes the coagulation protein factor XII, has been identified in familial cold urticaria and a bradykinin-dependent, rather than mast cell-dependent, pathomechanism has been proposed (see below). Cold-induced urticarial lesions also occur in familial cold autoinflammatory syndromes (FCASs) due to mutations in *NLRP3, NLRP12*, or *PLCG2*, thus implicating a role for the cryopyrin inflammasome and its production of IL-1β (see Tables 45.2 & 45.7)[35].

Cholinergic urticaria develops in response to stimulation of cholinergic sympathetic innervation of the sweat glands. How release of acetylcholine from the nerve endings leads to mast cell activation and histamine release is unknown. An allergy to sweat has been demonstrated by one group of investigators[36]. It has been proposed that pressure-induced wheals may be due to a late-phase reaction, but an antigen has never been identified. In three Lebanese families with autosomal dominant vibratory urticaria, a missense gain-of-function variant was detected in *ADGRE2* which encodes adhesion G protein-coupled receptor E2. This was thought to lead to destabilization of the inhibitory interaction between the alpha and beta subunits of ADGRE2, leading to sensitization of mast cells to vibration-induced degranulation[37].

The initiating event for spontaneous urticaria wheals is unclear but may involve plasma leakage due to local factors such as heat or pressure, which allows the extravasation of autoantibodies or IgE-directed antigens that then activate the IgE receptor, thus leading to mast cell degranulation and a subsequent urticarial response. As functional autoantibodies cannot be detected in ~70% of chronic urticaria sera by currently available tests, other mechanisms may operate in "non-autoantibody" urticaria, which, nevertheless, has a similar clinical presentation[38]. Increased plasma levels of prothrombin fragment 1 + 2 (F 1 + 2) and D-dimer (a measure of fibrinolysis) have been demonstrated in CSU[39] and relate to disease severity, but the contribution of coagulation abnormalities to the pathogenesis remains unclear. There are other serum factors in CSU patients that can activate mast cell lines *in vitro* and lead to endothelial activation, independent of IgE receptors on mast cells and the presence of IgG[40].

A popular hypothesis is that dietary food additives and natural salicylates as well as nonsteroidal anti-inflammatory drugs (NSAIDs) may cause urticaria via the diversion of arachidonic acid metabolism from prostaglandin to leukotriene formation. How this leads to urticaria is not clear, but it is known that intradermal injections of LTC_4, LTD_4, and LTE_4 cause whealing by a direct action on small blood vessels. There is some evidence from studies of rat peritoneal mast cells that PGE_2 can have inhibitory effects on immunologic mast cell degranulation[41], so a reduction in their formation may facilitate the latter. Aspirin can *aggravate* urticaria in up to 30% of patients with chronic disease, and while some clinical studies of dietary pseudoallergen avoidance have given encouraging results, the proportion of complete responders confirmed by rechallenge is small[42]. Aspirin allergy as a *cause* of urticaria is much less common, and the proportion of patients with urticaria due solely to pseudoallergens is probably low. Tolerance to NSAIDs is thought to be achievable in many CSU patients who are well controlled by H1 antihistamines[43].

Understanding "idiopathic" urticaria remains an important challenge. From a clinical perspective, it should be regarded as a multifactorial problem, and searching for aggravating factors is just as important as looking for causes.

Mast cell-independent urticaria

There are several recognized circumstances where angioedema or wheals are due to mechanisms that do not involve mast cells. These need special consideration because their management and prognosis are different. For example, prostaglandins are involved in the pathogenesis of some patterns of non-immunologic contact urticaria (e.g. to benzoic acid), and the latter can be suppressed by NSAIDs[44]. In the cryopyrin-associated periodic syndromes (CAPS; see below), patients often develop urticarial lesions. Systemic symptoms, such as fever, help to distinguish patients with autoinflammatory syndromes from those with CSU (see Ch. 45). The significant improvement that results from the administration of *anakinra*, an IL-1 receptor antagonist[45], *rilonacept*, a fusion protein that contains the extracellular domain of the IL-1 receptor and functions as an IL-1 trap[46], or *canakinumab*, a human anti-IL-1β monoclonal antibody[47], points to the role of the cryopyrin inflammasome and its production of IL-1β (see Figs. 4.2 & 45.13).

C1 esterase inhibitor (C1 inh) deficiency

C1 inh deficiency is usually hereditary but may be acquired. Two major forms of *hereditary* angioedema (HAE), types I and II, are primarily caused by mutations in one allele of the structural gene for C1 inh (*C1NH/SERPING1*) and are inherited in an autosomal dominant pattern. These mutations result in reduced levels of C1 inh (85% of cases; type I) or reduced C1 inh function (15% of cases; type II). Because these heterozygous mutations lead to levels that are 5%–30% of normal (rather than the expected 50%) in patients with type I HAE, it is thought that there is *trans* inhibition of the normal allele or increased catabolism of C1 inh. Rare families with autosomal recessive severe HAE and homozygous mutations have been reported.

Deficiency of C1 inh leads to loss of inhibition of factor XII (FXII; Hageman factor), resulting in the generation of bradykinin by the action of kallikrein on high-molecular-weight kininogen (Fig. 18.6). Activation of the C1 component of complement by proteolytic enzymes, including plasmin and FXIIa, leads to low levels of C4 in the serum, which is an almost constant feature between and during attacks in untreated patients.

HAE with normal C1 inh activity, also known as nC1-INH-HAE and previously referred to as type III HAE[48], is currently subclassified as HAE3 to HAE8 based upon underlying genetic mutations. HAE3 is due to *gain-of-function* mutations in one allele of the gene that encodes FXII, leading to increased formation of bradykinin (see Fig. 18.6). A positive feedback loop between kallikrein and FXII also contributes to the pathogenesis. One possible explanation for the preponderance of women with HAE3 is enhanced transcription of *F12* by estrogens. Mutations in *PLG*, *ANGPT1*, *KNG1*, *MYOF*, and *HS3St6* which encode plasminogen, angiopoietin-1, kininogen 1, myoferlin, and heparan sulfate 3-O-sulfotransferase 6 have also been described in HAE with normal C1 inh activity.

Acquired deficiency of C1 inh may result from activation of C1q and the complement cascade in patients with B cell lymphoproliferative disorders and plasma cell dyscrasias, or in those with autoimmune connective tissue diseases. This leads to *consumption* of C1 inh plus low

Downloaded for Anonymous User (n/a) at Egyptian Knowledge Bank from ClinicalKey.com by Elsevier on March 10, 2024. For personal use only. No other uses without permission. Copyright ©2024. Elsevier Inc. All rights reserved.

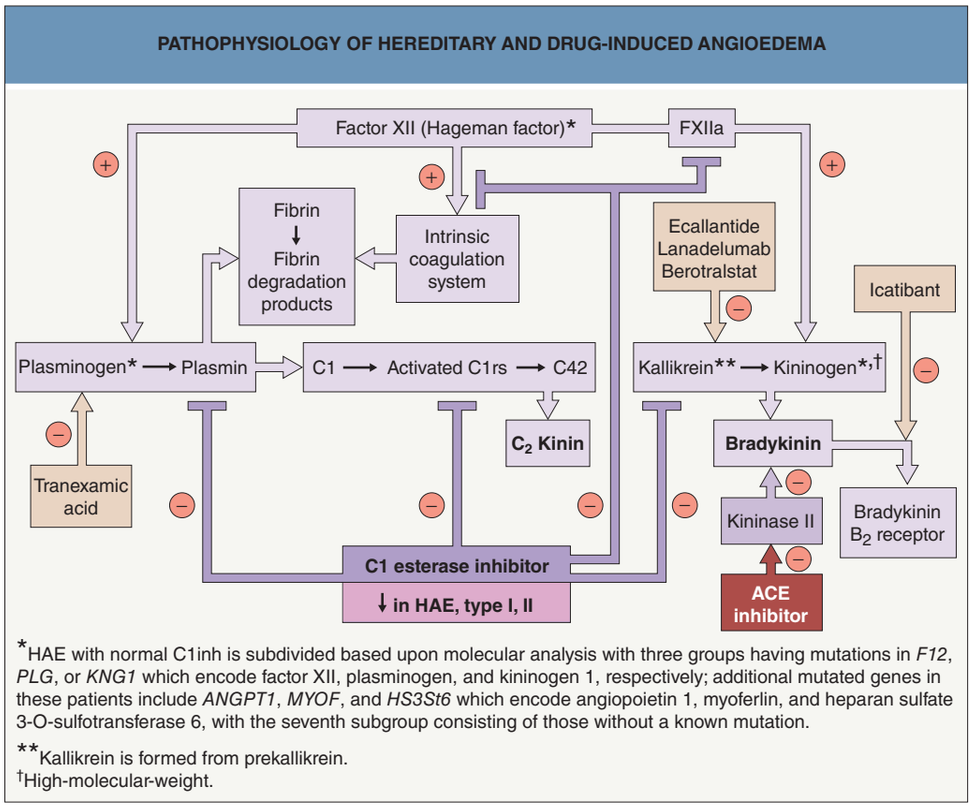

Fig. 18.6 Pathophysiology of hereditary and drug-induced angioedema. Angiotensin-converting enzyme (ACE) inhibitor-induced urticaria is believed to result from the inhibition of endogenous kininase and a subsequent increase in bradykinin. Intravenous C1 inh concentrate (derived from human plasma) or recombinant C1 inh (derived from milk of transgenic rabbits), subcutaneous icatibant (a decapeptide that is a specific bradykinin B_2 receptor antagonist), and subcutaneous ecallantide (a 60-amino acid recombinant kallikrein inhibitor) are options for the *emergency* treatment of hereditary angioedema (HAE). Subcutaneous or intravenous C1 inh (every 3–4 days), subcutaneous plasma kallikrein inhibitor lanadelumab (every 2 weeks), and oral kallikrein inhibitor berotralstat (150 mg daily) are options for *prevention* of attacks. ACE, angiotensin-converting enzyme; HAE, hereditary angioedema; inh, inhibitor.

serum levels of C1q as well as C4 (acquired, type I) or the formation of *inhibitory autoantibodies* directed against the C1 inh (acquired, type II).

Angiotensin-converting enzyme (ACE) inhibitor-induced urticaria is believed to result from the inhibition of endogenous kininase II (also known as ACE), which leads to increased production of bradykinin via inhibition of its metabolism (see Fig. 18.6). It usually presents with angioedema, which is usually orofacial and may be life-threatening.

CLINICAL FEATURES

Clinical Diversity

It is important to distinguish *urticaria* from *urticarial dermatoses*, such as urticarial drug eruptions, eosinophilic cellulitis, and the urticarial phase of pemphigoid. The individual wheals of urticaria are "here today and gone tomorrow" (i.e. they generally last <24 hours), whereas with urticarial dermatoses, the individual lesions may last for days or longer. Although urticarial vasculitis is often included in classifications of urticaria because the wheals resemble urticaria, it is actually an urticarial dermatosis. Clinically, the lesions last longer than 24 hours (as determined by circling and observing individual wheals), and histologically there is evidence of leukocytoclastic vasculitis (see Ch. 24).

Wheals may be small or large, as well as single or multiple. In the physical urticarias, the distribution pattern and morphology can be helpful in separating the different clinical types (see Inducible Urticarias). Angioedema can merge with wheals and these two can be difficult to separate, especially around the eyelids. Angioedema may also be a feature of anaphylaxis, if the throat is involved. In this sense, wheals, angioedema, and anaphylaxis form parts of a clinical spectrum resulting from mast cell activation.

Classification

Because the etiology is often unknown at the time of the first consultation, the most practical classification of urticaria relies on clinical characteristics rather than etiology when defining groups of patients (Table 18.2). Mostly, spontaneous urticaria can be considered to behave in an ordinary manner (i.e. fluctuating wheals which may be accompanied by angioedema) whatever its etiology or duration, unless it has a predominantly physical trigger, has evidence of vasculitis, or is caused by exogenous contact. If no cause for spontaneous urticaria can be defined, it is called idiopathic, but the use of this label as an automatic prefix to chronic urticaria is no longer tenable as a significant number of these patients are considered to have an autoimmune etiology as evidenced by functional basophil histamine release and activation assays (Table 18.3) or flow cytometry-based BAT. Elevated thyroid antibodies are also suggestive of autoimmune urticaria. It is worth separating angioedema without wheals from the other patterns of urticaria, because some of these cases will be due to HAE, acquired C1 inh deficiency, or drug reactions (e.g. ACE inhibitors, NSAIDs), and these are managed differently.

URTICARIA – CLINICAL CLASSIFICATION AND DIFFERENTIAL DIAGNOSIS
Clinical classification

• Spontaneous urticaria (all urticarias not classified below)
• Inducible urticarias (see Table 18.4)
  • Physical, non-physical (e.g. aquagenic), and cholinergic urticarias
  • Contact urticaria (induced by percutaneous or mucosal penetration)*

Differential diagnosis
• Urticarial drug eruption • Urticarial vasculitis (defined histologically by leukocytoclastic vasculitis) • Angioedema without wheals (e.g. hereditary angioedema, ACEi-induced angioedema) • Urticarial syndromes (e.g. autoinflammatory syndromes)
*Included within the inducible urticarias in the EAACI/GA²LEN/EDF/WAO Guideline[90].

Table 18.2 Urticaria – clinical classification and differential diagnosis. All clinical patterns of urticaria can be acute, episodic, or chronic. ACEi, angiotensin-converting enzyme (ACE) inhibitor.

Acute Versus Chronic Urticaria

All urticarias are acute initially. Some will become chronic after a period of time that is usually defined as 6 weeks or more. In a study from Korea, only a small proportion (7.8%) of patients with new-onset urticaria developed chronic urticaria during a 10-year follow-up period[49]. The term "chronic urticaria" should only be applied to continuous urticaria

Downloaded for Anonymous User (n/a) at Egyptian Knowledge Bank from ClinicalKey.com by Elsevier on March 10, 2024. For personal use only. No other uses without permission. Copyright ©2024. Elsevier Inc. All rights reserved.

TESTS EMPLOYED FOR AUTOIMMUNE URTICARIA				
Test		**Method**	**Strengths**	**Weaknesses**
Functional				
Basophil activation	Histamine release	Incubation of CSU sera with healthy donor basophils	• Test of CSU serum functionality – assumed IgG autoantibodies against FcεRI or IgE • Commercially available • May predict good response to cyclosporine	• Not specific for autoantibodies • May be present in patients with other illnesses and healthy individuals
	Basophil activation (CD203c or CD63)	Incubation of CSU sera with healthy donor basophils	• Test of CSU serum functionality – assumed IgG autoantibodies against FcεRI or IgE • Not commercially available outside the US	• No proven predictive value for treatment response
Autologous serum skin test (ASST)	Red wheal response to *autologous* serum	Intradermal *autologous* serum injection	• Visual demonstration of circulating serum factors and skin reactivity during CSU disease activity	• Not specific for functional antibodies or CSU • Not predictive of treatment response • No longer widely used due to concerns about safety of unregulated skin testing with blood products
Non-functional (and functional)				
Immunoassays	ELISA	IgG, IgM, and IgA autoantibodies against FcεRI and IgE	• Specific for autoantibody isotype and target antigens in CSU • Detects functional and non-functional antibodies	• Present in patients with other illnesses and healthy individuals • No proven utility for predicting treatment response • Not commercially available

Table 18.3 Tests employed for autoimmune urticaria. CSU, chronic spontaneous urticaria; ELISA, enzyme-linked immunosorbent assay.

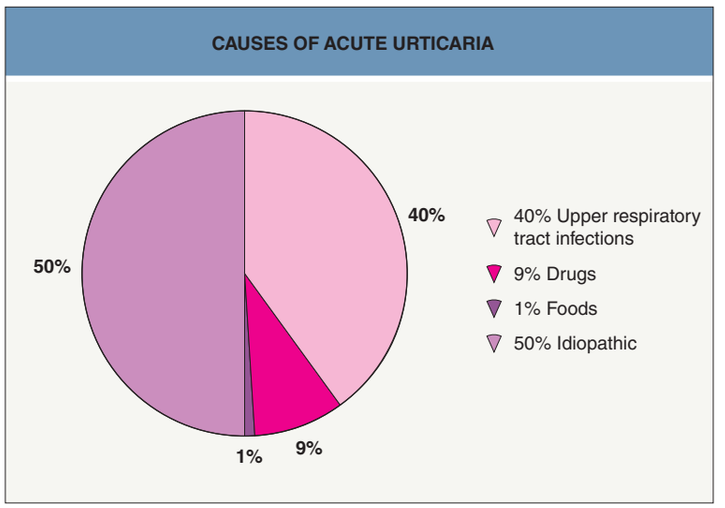

Fig. 18.7 Causes of acute urticaria. *Data from Zuberbier T, Iffländer J, Semmler C, Henz BM. Acute urticaria: clinical aspects and therapeutic responsiveness. Acta Derm Venereol 1996;76:295–7.*

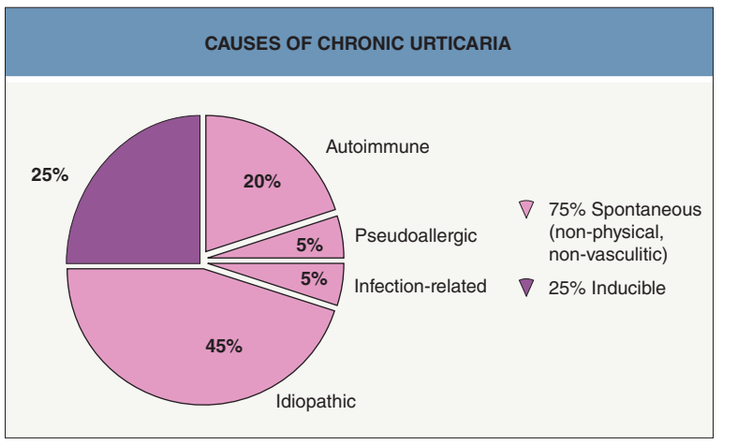

Fig. 18.8 Causes of chronic urticaria. Autoimmune represents those patients with functional autoantibodies against FcεRI or the Fc portion of IgE.

occurring at least twice a week off treatment. Urticaria occurring less frequently than this over a long period is better called episodic (or recurrent), because this presentation may be more likely to have an identifiable environmental cause.

The causes of *acute* urticaria in adults presenting to emergency dermatology clinics in one survey are shown in Fig. 18.7[50,51]. Most of these patients probably fall into the spontaneous category, because physical urticarias and urticarial vasculitis tend to persist beyond 6 weeks and contact urticarias would not normally present as an emergency. The high frequency of associated viral infections is notable, as is the lack of food allergy as a cause. The different clinical patterns of *chronic* urticaria and their causes (where known) are shown in Fig. 18.8. These data reflect the experience of specialist urticaria clinics in dermatology departments and may not represent the experience of other medical practitioners, such as those in general practice, internal medicine, pediatrics, or allergy.

Spontaneous Urticaria

The condition can present at any age. Acute urticaria is common in young atopic children but chronic urticaria peaks in the fourth decade. Multiple pruritic wheals of different sizes erupt anywhere on the body and then fade within 2–24 hours without bruising; angioedema may last up to 72 hours when severe. In literature reviews, isolated urticaria occurred in ~50% of patients, urticaria plus angioedema in ~40%, and angioedema alone in the remainder[52,53]. Wheals may occur at any time, but often appear in the evening or are present on waking. Irritation tends to be most intense at night and may disturb or prevent sleep. This, in turn, compounds the distress of the condition. Substantial impairment in quality-of-life measures, including self-image, sexual relationships, and social interactions, has been demonstrated. Women may describe premenstrual exacerbations. Systemic symptoms of fatigue, lassitude, sweats and chills, indigestion, myalgia, or arthralgia may occur with severe attacks[54], but the occurrence of pyrexia or arthritis should alert the clinician to another explanation, such as urticarial vasculitis or neutrophilic urticarial dermatosis due to Schnitzler syndrome, Still disease, or CAPS.

Associations and comorbidities

Chronic spontaneous urticaria has been associated with autoimmune thyroid disease[55] and other autoimmune conditions, including vitiligo, insulin-dependent diabetes, rheumatoid arthritis, and pernicious anemia[56]. Those chronic urticaria patients with demonstrable histamine-releasing autoantibodies have a very strong association with HLA DRB1*04 (DR4) and its associated allele DQB1*0302 (DQ8)[57]. A possible association between *Helicobacter pylori* gastritis and chronic urticaria was suggested by a systematic review of therapeutic studies,

Downloaded for Anonymous User (n/a) at Egyptian Knowledge Bank from ClinicalKey.com by Elsevier on March 10, 2024. For personal use only. No other uses without permission. Copyright ©2024. Elsevier Inc. All rights reserved.

which showed a higher frequency of urticaria remission when the infection was eradicated than when it was not[58]. Parasitic infections, in particular protozoa (e.g. *Blastocystis hominis*, *Giardia* spp.), are an uncommon cause of urticaria in high-income countries, but may be a significant problem where they are endemic. Acute urticaria due to gastric *Anisakis simplex* has been reported from Spain[59]. Possible associations between dental infections or gastrointestinal candidiasis and chronic urticaria have not been substantiated by large epidemiologic studies.

Although there have been anecdotal reports linking urticaria to malignancy[60], no statistically significant association was found in a Swedish survey[61]. However, an increased risk of hematologic malignancies, especially non-Hodgkin lymphoma, was noted in a large retrospective cohort study of a National Insurance database in Taiwan[62]. Atopic diseases[63], metabolic syndrome[64], and psychiatric disorders (especially anxiety and depression)[65] are reported comorbidities in chronic urticaria.

Inducible Urticarias (syn. Physical Urticarias)

These urticarias represent a distinct subgroup of urticaria that is induced by an exogenous stimulus rather than occurring spontaneously. This section discusses physical triggers while the next section reviews other chemical and protein stimuli. Because cholinergic urticaria is triggered by factors that lead to sweating (e.g. a rise in core body temperature, stress, spicy foods), rather than an external physical stimulus, it is often classified separately from other inducible urticarias. The inducible urticarias are classified by the predominant stimulus that triggers whealing, angioedema, or anaphylaxis[66] (Table 18.4). Of all the urticarias, they may affect the quality of life most severely, particularly delayed pressure urticaria and cholinergic urticaria[67]. While the lesions of most physical urticarias occur within minutes of provocation and generally resolve within 2 hours, a few physical urticarias (e.g. delayed pressure urticaria, delayed dermographism) develop after a delay of several hours and persist for 24 hours or longer.

The wheals are usually localized to the stimulated area of skin. However, sometimes the physical stimuli need to produce a systemic effect, e.g. a rise or drop in core body temperature, to induce urticaria of a reflex type. Thus, generalized heating of the body can induce cholinergic urticaria (which is common), and generalized cooling, cold reflex urticaria (which is rare). Here, multiple small wheals occur on widespread areas of the body.

Angioedema may be seen with all the physical urticarias except with symptomatic dermographism. Vibratory angioedema manifests with subcutaneous swellings but not wheals. Also, several forms of physical urticaria can coexist in the same patient. Common combinations include: (1) symptomatic dermographism and cholinergic urticaria; and (2) cold and cholinergic urticaria. In addition, delayed pressure urticaria may coexist with CSU. Some rare forms of physical urticaria, such as familial delayed cold urticaria, are beyond the scope of this chapter.

CLASSIFICATION OF INDUCIBLE URTICARIAS
Urticaria due to mechanical stimuli

Dermographism
• Immediate
  • Simple
  • Symptomatic
• Delayed
Delayed pressure urticaria
Vibratory angioedema
• Inherited
• Acquired

Urticaria due to temperature changes

Heat
• Heat contact urticaria
Cold
• Cold contact urticaria
  • Primary
  • Secondary (cryoproteins)

Urticaria due to sweating or stress
Cholinergic urticaria Adrenergic urticaria Exercise-induced urticaria • Exercise-induced anaphylaxis • Food- and exercise-induced anaphylaxis
Contact urticaria
Solar urticaria
Aquagenic urticaria
Rare variants are not shown here for simplicity.

Table 18.4 Classification of inducible urticarias by the eliciting stimulus.

Urticaria due to mechanical stimuli

Dermographism (literally "skin writing") (syn. dermatographism, factitious urticaria)

Immediate dermographism

This is divided into simple or symptomatic. *Simple* immediate dermographism occurs in at least 5% of the normal population in response to moderate stroking of the skin and may be regarded as an exaggerated physiologic response and is typically not pruritic.

Symptomatic immediate dermographism is the most common type of physical urticaria (Fig. 18.9). It manifests as pruritic linear wheals at sites of scratching or sites of friction, such as collars and cuffs of clothes. Whealing occurs after gentle stroking of the skin in response to a shearing force. Patients, most frequently young adults, often complain of pruritus before the wheals appear and may not associate them with scratching. It is worst in the evening and often occurs in bouts. The lesions usually resolve within an hour. Oral mucosal involvement does not occur, but vulvodynia and swelling during sexual intercourse has been reported[68].

The general course is unpredictable, but usually there is a gradual tendency towards improvement over several years. Symptomatic dermographism occasionally follows scabies infestation and penicillin allergy reactions. There is no association with systemic disease, atopy, food allergy, or autoimmunity.

Rarer forms of dermographism

These include delayed dermographism, which appears at least 30 minutes after a stroking stimulus, red dermographism (in response to rubbing, not stroking, the skin), localized dermographism, cholinergic dermographism, and Darier's sign (a localized dermographic response after gentle rubbing of cutaneous mastocytosis lesions). The blanching response seen in patients with atopic and other forms of dermatitis, known as white dermographism, is not a form of urticaria nor is black dermographism in which there is dark discoloration of the skin due to surface deposition of metallic particles.

Delayed pressure urticaria

Delayed pressure urticaria (DPU) is important because it can interfere severely with quality of life; it may be underdiagnosed and its treatment is difficult[69]. DPU is characterized by the development of deep

Fig. 18.9 Symptomatic immediate dermographism. Itchy wheals appear very soon after scratching. *Courtesy Jean L. Bolognia, MD.*

Downloaded for Anonymous User (n/a) at Egyptian Knowledge Bank from ClinicalKey.com by Elsevier on March 10, 2024. For personal use only. No other uses without permission. Copyright ©2024. Elsevier Inc. All rights reserved.

Fig. 18.10 Delayed pressure urticaria.

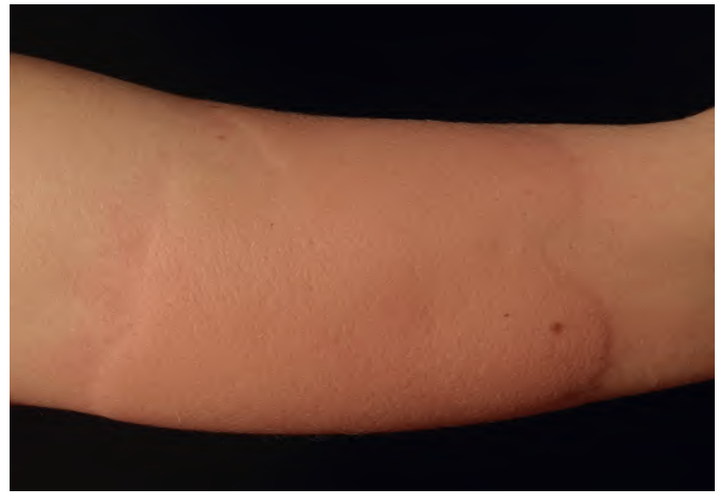

Fig. 18.11 Cold urticaria. Wheals developed on the forearm after placement of an ice cube for 10 minutes, followed by rewarming. *Courtesy Thomas Schwarz, MD.*

erythematous swellings at sites of sustained pressure to the skin, after a delay of 30 minutes to 12 hours (Fig. 18.10); sometimes it resembles angioedema. The swellings are usually pruritic, painful, or both, and may persist for several days, unlike the spontaneous wheals of ordinary urticaria. Sites frequently involved are the waistline after wearing tight clothing, below the elastic of socks, the feet in tight shoes, the palms after manual work, the soles after walking or climbing ladders, and the genitalia after intercourse.

Rarely, systemic features such as malaise, "flu-like" symptoms, and arthralgia may occur. If the swellings develop over joints, the resulting restriction of motion may be mistaken for arthritis. The prognosis is variable, but the mean duration in different series was 6–9 years. Up to 35% of patients with CSU attending a hospital specialist clinic had associated DPU. Conversely, nearly all patients with DPU have associated spontaneous wheals. Because of this association and the delayed onset, patients may not be aware of any relationship to pressure unless specifically questioned.

Vibratory angioedema

This is a very rare form of urticaria, where a vibratory stimulus induces localized swelling and erythema within minutes, lasting 30 minutes. Stimuli include jogging, vigorous rubbing with a towel, and the use of vibrating machinery such as lawnmowers and motorcycles. Avoidance of vibratory stimuli enables patients to live a normal life. Vibratory angioedema may be acquired or familial. The acquired form is often milder, and it may be associated with other physical urticarias such as DPU and symptomatic immediate dermographism. The familial form is dominantly inherited, has its onset during infancy, and intense vibratory stimuli may induce generalized erythema and systemic symptoms such as headaches[70]. Pathogenic variants in *ADGRE2*, which encodes adhesion G protein-coupled receptor E2, have been detected (see Pathogenesis).

Urticaria due to temperature changes

Heat exposure

Heat contact urticaria

This is one of the rarest forms of urticaria. Within minutes of contact with heat from any source, itching and whealing occur at the site of contact, lasting up to 1 hour. This must be distinguished from cholinergic urticaria. Patients can present after contact with hot water (e.g. washing dishes), but also after contact with radiant heat or warm sunlight. Systemic symptoms of faintness, headache, nausea, and abdominal pain have occurred when the urticaria is extensive. There is an even rarer delayed form[71].

Cold exposure

Cold urticaria represents a heterogeneous group of conditions in which whealing occurs within minutes of rewarming after cold exposure[72]. There are both typical and atypical forms, with the latter group constituting ~30% of cases and being characterized by negative provocation tests. Typical forms are primary cold contact urticaria and secondary cold contact urticaria, while atypical forms are systemic atypical acquired cold urticaria, cold-dependent dermographism, cold-induced cholinergic urticaria, delayed cold urticaria, and localized cold reflex urticaria[73].

Primary cold contact urticaria

The most commonly encountered form is primary cold contact urticaria; it accounts for at least 95% of cases (Fig. 18.11). Although cold urticaria may follow respiratory infections, arthropod bites or stings, and perhaps HIV infection, the cause of most cases remains unknown (idiopathic). It may occur at any age, but is most frequently seen in young adults. Itching, burning, and whealing occur in cold-exposed areas minutes after rewarming the skin. Commonly, primary cold contact urticaria occurs in rainy, windy weather and after contact with cold objects or drinking cold liquids. Patients often relate symptoms to changes in temperature as much as to the absolute external temperature. Systemic symptoms of flushing, headache, syncope, and abdominal pain can develop if large areas are affected. Cold baths and swimming should usually be avoided as there is a potential risk of anaphylaxis. The mean duration was 6–9 years in one series, though primary cold contact urticaria may be more transient if it follows a viral infection.

Secondary cold contact urticaria

Cases due to cryoproteinemia are rare, and they are associated with other manifestations such as Raynaud phenomenon or purpura. The wheals are usually similar to those of primary cold contact urticaria, but may last longer. The presence of circulating cryoglobulins should be determined and if detected, underlying causes, such as hepatitis B or C viral infections, lymphoproliferative disease, or infectious mononucleosis, should be excluded.

Reflex cold urticaria

In this form, generalized cooling of the body induces widespread whealing. Patients with this disorder can experience life-threatening reactions from exposures such as diving into a cold lake. The ice cube test is negative, but placing the patient in a cold room at 4°C can reproduce lesions; however, one should exert caution because anaphylaxis could occur.

Familial cold urticaria

Familial cold urticaria, also referred to as familial cold autoinflammatory syndrome (FCAS), belongs to the group of disorders known as cryopyrin-associated periodic syndromes (CAPS) (see Table 45.2). The patients with FCAS1 have mutations in *NLRP3*, which encodes the inflammasome protein cryopyrin, and they develop cold-induced urticaria wheals. FCAS2 and FCAS3 are due to mutations in *NLRP12* and *PLCG2*, respectively; the latter encodes a phospholipase (see Table 45.7). Lastly, *gain-of-function* mutations in *F12* have been detected in families with either HAE3 or cold-induced urticarial lesions and systemic symptoms[35].

Downloaded for Anonymous User (n/a) at Egyptian Knowledge Bank from ClinicalKey.com by Elsevier on March 10, 2024. For personal use only. No other uses without permission. Copyright ©2024. Elsevier Inc. All rights reserved.

Urticaria due to sweating or stress

Cholinergic urticaria

Cholinergic urticaria is characterized by multiple, transient, papular wheals that are 2–3 mm in diameter and surrounded by an obvious flare. They occur within 15 minutes of sweat-inducing stimuli, such as any form of physical exertion, hot baths, or sudden emotional stress (Fig. 18.12). Other eliciting stimuli include moving from a cold to a hot room, drinking alcohol, and eating spicy food. It occurs more frequently in young adults with an atopic diathesis and is unusual in the elderly. It may be associated with acquired generalized hypohidrosis (see Table 39.11)[74].

After the appropriate stimulus, pruritus is followed by the development of small, monomorphic wheals that are symmetrically distributed. They are most prominent on the upper half of the body, but can also affect the lower legs and forearms and even become generalized. Angioedema and systemic manifestations consisting of faintness, headache, palpitations, abdominal pain, and wheezing may occur. Reduced forced expiratory volumes (in the absence of respiratory symptoms) have been recorded by spirometry. In more severely affected individuals, cholinergic urticaria can cause severe personal and occupational disability.

Cold urticaria, symptomatic dermographism, or aquagenic urticaria may be associated with cholinergic urticaria. There is usually a gradual tendency towards improvement, but the condition may last for years. Rarer forms include cholinergic pruritus, cholinergic erythema (in which pruritic, symmetric, small erythematous macules appear to be persistent, but individual lesions actually last for up to 1 hour), and cholinergic dermographism. Severe exercise-induced cholinergic urticaria may sometimes progress to anaphylaxis.

Exercise-induced anaphylaxis (EIA)

This can occur without the typical wheals of cholinergic urticaria and appears to be a syndrome in its own right. Food- and exercise-induced anaphylaxis (FEIA) is an increasingly recognized syndrome[75]. In FEIA, angioedema and/or anaphylaxis occur within minutes of exercise if it follows either prior ingestion of a specific food (e.g. α-gliadin in wheat), or sometimes within 4 hours of a heavy meal. FEIA may be due to priming of the mast cell by either prior exposure to an allergen or an unknown mechanism. EIA is produced by exercise, but not by an increase in core temperature induced by other means capable of provoking cholinergic urticaria (e.g. passive overheating in a hot bath), and this distinction can be used to differentiate between the two conditions.

Adrenergic urticaria

Adrenergic urticaria can be distinguished from cholinergic urticaria by the presence of blanched vasoconstricted skin surrounding small pink wheals induced by sudden stress, as opposed to pale wheals surrounded by a pink halo. The lesions can be reproduced by intradermal injections of norepinephrine (noradrenaline).

Urticaria due to other exposures

Solar urticaria

Itching and whealing occur within minutes of exposure to ultraviolet or visible wavelengths of solar radiation specific to the patient (see Ch. 87).

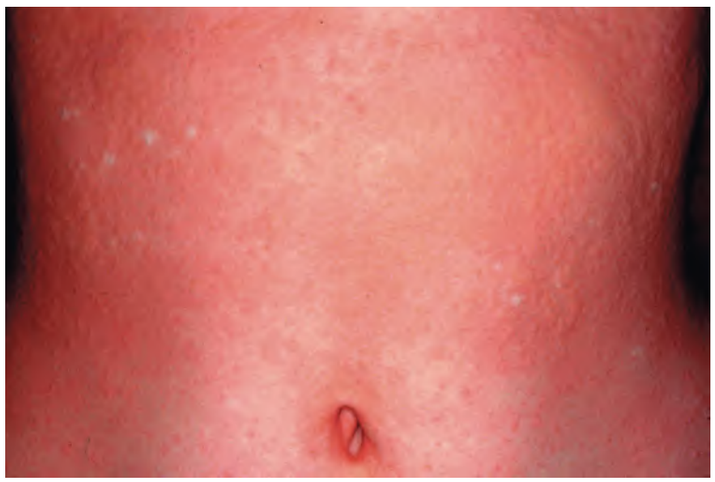

Fig. 18.12 Cholinergic urticaria on the trunk after hot bath provocation.

Aquagenic urticaria

In aquagenic urticaria, contact with water of any temperature induces an urticarial eruption resembling a sparse form of cholinergic urticaria, with large flares around papular wheals. Lesions occur most frequently on the upper part of the body and last for less than an hour. Other physical urticarias must be excluded and the condition must be differentiated from aquagenic pruritus (see Ch. 6).

Contact Urticaria (see Ch. 16)

Contact urticaria is defined by the development of urticaria at the site(s) of contact with skin or mucosa but contact erythema and even burning and stinging without erythema are sometimes embraced in the definition[44]. Percutaneous or mucosal penetration of the urticant may have distant effects, including acute urticaria or even anaphylaxis. Contact urticaria may be more common than reported, as patients often do not present to the hospital or tertiary care clinics, because the diagnosis is usually self-evident.

Immunologic and non-immunologic forms are recognized, depending on whether the contact urticaria is due to allergen interaction with specific IgE or is IgE-independent. *Immunologic* (i.e. allergic) contact urticaria can be seen in children with atopic dermatitis who become sensitized to environmental allergens, such as grass, animals and foods, or in glove-wearers who are allergic to latex. In those individuals repeatedly exposed to latex via mucosal surfaces (e.g. urinary catheterization in spina bifida patients), allergic contact urticaria can be complicated by anaphylaxis. *Non-immunologic* (i.e. non-allergic) contact urticaria is due to direct effects of urticants on blood vessels, such as from exposure to either sorbic acid and benzoic acid in eye solutions and foods or cinnamic aldehyde in cosmetics; it may be mediated by PGD_2 and can be inhibited by NSAIDs. Percutaneous microinjection of histamine, acetylcholine, and/or serotonin by nettle stings as well as contact with histamine liberators that degranulate mast cells (e.g. dimethylsulfoxide, cobalt chloride) can result in contact urticaria.

Food contact hypersensitivity syndrome

The oral allergy syndrome, also referred to as pollen–food allergy syndrome, presents with itching and mild swelling of the mouth, tongue, and soft palate within minutes of eating fresh fruits such as apples, pears, peaches, and cherries, but not cooked fruit. It usually occurs in hay fever sufferers and represents a cross-reaction between fruit proteins and panallergens in grass (profilin) or birch pollen allergens, in particular Bet v 1, a member of the PR-10 family. Angioedema and anaphylaxis are fortunately very rare. The term "food contact hypersensitivity syndrome" was proposed to include all forms of immediate mucosal food contact reactions, including oral allergy syndrome[76].

Angioedema Without Wheals

Recurrent angioedema without wheals is in most instances idiopathic, but it is important to exclude a drug reaction and to consider the possibility of C1 inhibitor (inh) deficiency. The latter can be inherited or acquired (e.g. B cell lymphoproliferative disorders, plasma cell dyscrasias, autoantibodies against C1 inh).

Drug reactions

A number of drugs can cause angioedema without wheals. The most common are NSAIDs[77] and ACE inhibitors (see Fig. 18.6)[78]. Aspirin intolerance may present with angioedema alone, or with urticaria or anaphylaxis; cross-reactions with other NSAIDs can occur. A causative link to ACE inhibitors may be overlooked because angioedema can present over a year after starting the medication and occasionally even years later. An increased risk of ACE inhibitor-induced angioedema has been observed when the latter is coadministered with dipeptidyl peptidase-4 inhibitors ("gliptins") and mTOR inhibitors[79,80]. ACE inhibitors are contraindicated in patients with HAE and acquired C1 inh deficiency, and for practical purposes, ACE inhibitors should be discontinued in favor of other antihypertensive medications if angioedema occurs without wheals.

Angiotensin receptor blockers (ARBs) such as valsartan and losartan are also associated with development of angioedema. Depending upon the study, the risk of ARB-induced angioedema in patients with ACE inhibitor-induced angioedema varies from 0–15%. As a result, ARBs are

Downloaded for Anonymous User (n/a) at Egyptian Knowledge Bank from ClinicalKey.com by Elsevier on March 10, 2024. For personal use only. No other uses without permission. Copyright ©2024. Elsevier Inc. All rights reserved.

avoided in such patients. As with other drug eruptions, it is important to consider exposure via combination drugs, in this case sacubitril–valsartan, which is increasingly being used to treat congestive heart failure. Of note, an increased incidence has been reported in Black patients[81].

Hereditary angioedema (HAE), types I and II (inherited C1 inh deficiency)

The likelihood of inherited C1 inh deficiency as a cause of recurrent angioedema is increased if there is a family history or previous laryngeal edema or colicky abdominal pain (sometimes presenting as a surgical emergency). Trauma (emotional or physical) and estrogens can trigger attacks. The usual duration is 48–72 hours, and episodes are often followed by a refractory period. Some families with HAE describe a transient, prodromal erythematous eruption, but urticaria whealing does not occur and so a history of recurrent wheals effectively excludes the disorder.

Hereditary angioedema (HAE) with normal C1 inh activity (nC1-INH-HAE; previously type III)

This form of HAE currently has seven subgroups, six of which are associated with mutations in the genes that encode factor XII, plasminogen, angiopoietin-1, kininogen 1, myoferlin, and heparan sulfate 3-O-sulfotransferase 6 (see above). The seventh group includes those whose genetic basis is unknown. Compared to patients with an inherited deficiency of C1 inh, the age of onset is later (usually in or after the second decade) and there is a higher frequency of facial angioedema.

Distinctive Syndromes with Urticarial Lesions

Hereditary periodic fever syndromes

Cryopyrin-associated periodic syndromes (CAPS)

The allelic disorders Muckle–Wells syndrome, familial cold autoinflammatory syndrome (familial cold urticaria), and neonatal-onset multisystem inflammatory disease (NOMID/CINCA) are all now known to be due to mutations in *NLRP3*, which encodes the protein cryopyrin (see Table 45.2)[82]. These patients can develop wheals from an early age that are resistant to antihistamines.

Other syndromes

In hyperimmunoglobulinemia D with periodic fever syndrome (HIDS) due to partial mevalonate kinase deficiency as well as TNF receptor-associated periodic syndrome (TRAPS), erythematous and edematous urticarial plaques can occur in addition to periorbital edema (in TRAPS). The cutaneous lesions in familial Mediterranean fever are more erysipelas-like in appearance (see Table 45.2).

Acquired autoinflammatory syndromes

Schnitzler syndrome

Schnitzler and colleagues in 1974 described an unusual variant of chronic urticaria characterized by recurrent, non-pruritic wheals plus intermittent fevers, bone pain, arthralgia or arthritis, an increased ESR, and an IgM monoclonal gammopathy[83]. Occasionally, there is an IgG paraprotein. The Strasbourg validated diagnostic criteria for Schnitzler syndrome consist of two major criteria – urticarial rash and IgM or IgG monoclonal gammopathy – and four minor criteria – recurrent fever >38°C without any other cause, changes in bone structure visible in imaging ± bone remodelling, neutrophilic dermal infiltrate, and leukocytosis and/or elevated CRP. Confirming the diagnosis requires both major and at least two minor criteria (if IgM) or at least three minor criteria (if IgG). If the two major criteria are accompanied by only one minor criterion (if IgM) or two minor criteria (if IgG), the diagnosis is considered probable[84]. Some of the patients with Schnitzler syndrome will have an MYD88 L265P variant.

The clinical presentation overlaps with that of the CAPS group of inherited autoinflammatory disorders. While skin biopsy specimens usually show a neutrophil-predominant dermal infiltrate without edema, fully developed small vessel vasculitis is not seen. Some clinicians believe that these patients are best considered as having a variant of neutrophilic urticaria while others prefer the term neutrophilic urticarial dermatosis (see Table 45.6). Schnitzler syndrome responds very well to IL-1 blockade, e.g. anakinra, canakinumab, rilonacept.

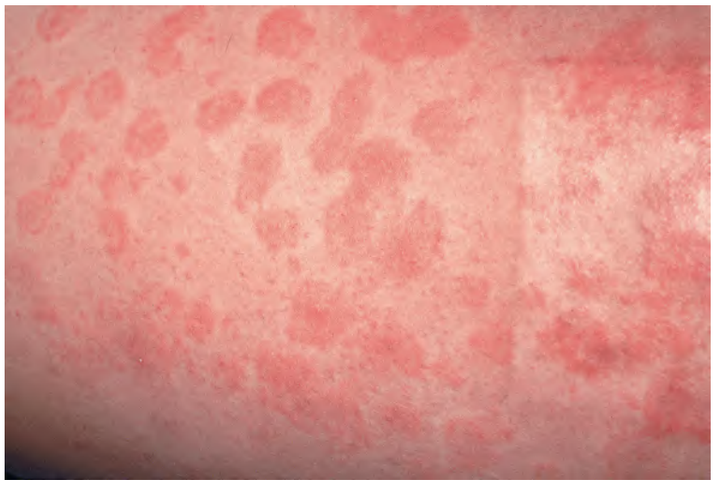

Fig. 18.13 Urticarial vasculitis. Lesions look like spontaneous urticaria but last longer and may bruise. An incidental finding is a skin graft donor site.

Adult-onset Still disease

This is a rare acquired autoinflammatory disorder in which patients present with fever, a sore throat, an often evanescent urticarial eruption, arthritis, lymphadenopathy, and hyperferritinemia (see Ch. 45).

Episodic angioedema with eosinophilia (Gleich syndrome)

A syndrome of episodic angioedema with hypereosinophilia, weight gain, and fever has been described. The cause is uncertain, but increased serum levels of IL-5 have been noted[85].

Systemic capillary leak syndrome

Also known as Clarkson syndrome, this rare acquired disorder is characterized by episodic massive plasma exudation from blood vessels, leading to potentially life-threatening hypotension, analogous to anaphylaxis. Angioedema may be a feature. It is associated with an IgG paraproteinemia. Medications, in particular IL-2, can also produce a systemic capillary leak syndrome.

Urticarial vasculitis (see Ch. 24)

Urticarial vasculitis is a clinicopathologic entity in which cutaneous lesions resemble urticaria clinically, but last longer than 24 hours and may resolve with postinflammatory hyperpigmentation or purpura (Fig. 18.13). Histologically, there is evidence of leukocytoclastic vasculitis. Extracutaneous manifestations, especially in the setting of hypocomplementemia, may include arthralgias, abdominal pain, obstructive pulmonary disease, glomerulonephritis, and uveitis or episcleritis.

PATHOLOGY

The histopathology of urticaria is characterized by upper dermal edema with a mild mixed perivascular infiltrate of lymphocytes, eosinophils, basophils, and some neutrophils (Fig. 18.14). A predominantly neutrophilic pattern has been described in a minority of patients (see below)[86]. Previous reviews of biopsy specimens from large series of patients with chronic urticaria have emphasized a spectrum of changes, ranging from mild lymphocytic infiltrates with rare neutrophils to occasionally showing fully developed leukocytoclastic vasculitis[87], pointing to some histopathologic overlap between chronic urticaria and urticarial vasculitis. Features of the latter include endothelial cell damage, a perivenular cellular infiltrate rich in neutrophils, swelling of vessel walls, and leukocytoclasis. Extravasation of erythrocytes and fibrinoid deposits in and around blood vessels may also be seen.

The term *neutrophilic urticaria* is sometimes used when biopsy specimens of urticaria contain predominantly neutrophilic dermal infiltrates but lack features of vasculitis[88]. Although this pattern did not appear to have clinical or etiologic significance[68], neutrophilic urticaria overlaps with *neutrophilic urticarial dermatosis*. This term is used to describe an aseptic, interstitial, perivascular, and peri-appendageal neutrophilic infiltrate with nuclear dust and neutrophils within dilated dermal blood vessels, but without vasculitis. The latter occurs

Downloaded for Anonymous User (n/a) at Egyptian Knowledge Bank from ClinicalKey.com by Elsevier on March 10, 2024. For personal use only. No other uses without permission. Copyright ©2024. Elsevier Inc. All rights reserved.

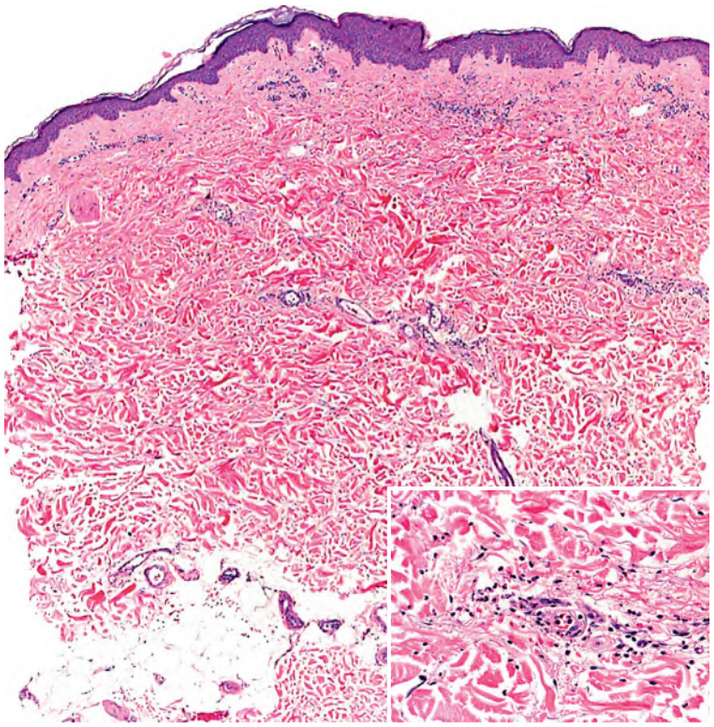

Fig. 18.14 Spontaneous urticaria – histologic findings. A sparse, mainly perivascular inflammatory infiltrate and scant edema within the superficial and mid dermis. Note several neutrophils and a few eosinophils (inset). *Courtesy Lorenzo Cerroni, MD.*

in the setting of inherited acquired and inherited autoinflammatory syndromes (e.g. CAPS, Schnitzler syndrome, Still disease; see Table 45.6) as well as occasionally in systemic lupus erythematosus.

DIAGNOSIS AND DIFFERENTIAL DIAGNOSIS

The differential diagnosis of urticaria includes all dermatologic conditions with an urticarial component, including insect bite reactions (papular urticaria), urticarial drug reactions, pre-bullous phase of pemphigoid (i.e. urticarial pemphigoid), urticarial vasculitis, autoinflammatory syndromes, eosinophilic cellulitis (Wells syndrome), polymorphic eruption of pregnancy, acute eyelid contact dermatitis (versus angioedema), and the urtication that may occur when lesions of urticaria pigmentosa are rubbed. In all these conditions, the urticarial component is part of a more prolonged inflammatory process (or mast cell proliferation in the case of mastocytosis) than in true urticaria and should be readily distinguishable by the prolonged duration of individual lesions or associated systemic findings. Especially in young children, urticaria may develop a dusky center (urticaria multiforme; Fig. 18.15; see Table 20.3) and be confused with erythema multiforme, serum sickness-like reaction, or hemorrhagic edema of infancy.

Diagnosis

A comprehensive history is essential in every patient with urticaria. It should cover the duration of disease, frequency of attacks, duration of individual lesions, medications, known allergies, past and family history including comorbidities, previous treatments and responses, occupation and leisure activities, and an assessment of the impact of the disease on the patient's quality of life. The use of a detailed questionnaire in conjunction with a complete blood count and ESR was found to be almost as good as a complete diagnostic evaluation[89]. A full physical examination looking for the morphology and duration (by circling individual lesions) of wheals, bruising, livedo reticularis, and signs of systemic disease should always be undertaken, but it is often normal. The patient's own photographs can often be useful because it is common for urticaria to have cleared by the time of consultation. Investigation should be targeted at specific features identified in the clinical assessment, as outlined below, and may include blood tests, skin biopsy (obtained in all patients with lesions consistently lasting more than 24 hours), challenges for physical urticarias, food additives, and drugs, and, infrequently as an extended investigation, skin tests for allergy and measurement of histamine-releasing autoantibodies[90]. Most patients with antihistamine-responsive urticaria do not need an extensive investigation. A diagnostic algorithm is given in Fig. 18.16.

Fig. 18.15 Urticaria in a young child. This clinical presentation of urticaria is sometimes misdiagnosed as erythema multiforme because of the dusky centers, with some clinicians referring to it as urticaria multiforme. As lesions expand, central clearing can occur, which is not seen in erythema multiforme. *Courtesy Luis Requena, MD.*

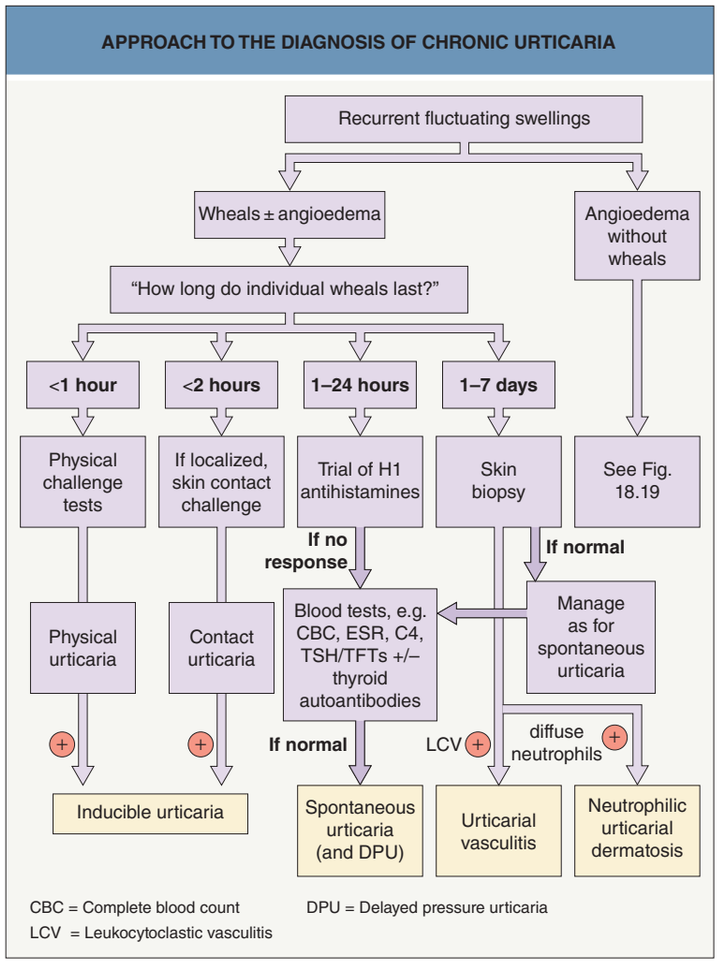

Fig. 18.16 Approach to the diagnosis of chronic urticaria.

Downloaded for Anonymous User (n/a) at Egyptian Knowledge Bank from ClinicalKey.com by Elsevier on March 10, 2024. For personal use only. No other uses without permission. Copyright ©2024. Elsevier Inc. All rights reserved.

Acute urticaria

No routine laboratory tests are recommended for acute urticaria but when a type 1 allergic reaction to environmental allergens is suspected as the cause of acute urticaria or contact urticaria, skin prick testing and measurement of specific IgE antibodies (e.g. ImmunoCAP®) can be performed.

Chronic urticaria

No investigations are routinely required for the majority of patients with mild disease that responds to antihistamines. A useful screening profile for non-responders with more severe disease could include a complete blood count with differential (for instance, to detect the eosinophilia of intestinal parasitosis) and ESR (usually normal in CSU). The ESR may be elevated in urticarial vasculitis, and it is consistently high in symptomatic acquired and genetic autoinflammatory syndromes in which patients also have an elevated C-reactive protein level (usually >30 mg/l). Measurement of thyroid autoantibodies and thyroid function tests should be performed if indicated clinically. The prevalence of thyroid autoantibodies is higher in patients with chronic urticaria than in controls and may be an indicator of autoimmune urticaria. Tests for helminths may be considered in the appropriate clinical setting. Although evidence is equivocal that *Helicobacter pylori* infection can be associated with CSU, patients with hyperacidity should be tested since eradication therapies may lead to urticaria remission.

Although the term "autoimmune" urticaria is increasingly being used for patients with evidence of functional serum autoantibodies (see Fig. 18.3 & Table 18.3), there is still a lack of agreement with regard to definitively establishing such a diagnosis. Demonstration of autoreactivity in the form of a localized wheal and flare response to intradermal injection of autologous serum (autologous serum skin test [ASST]) provides useful evidence of functional factors in the blood but is not specifically a test for functional autoantibodies[91] (Fig. 18.17). A negative test, however, has very good negative predictive value for the absence of functional autoantibodies[92]. However, stricter regulatory guidelines regarding the handling of blood products will increasingly limit performance of this assay.

Immunoassays for anti-FcεRI and anti-IgE antibodies do not necessarily correlate with basophil and mast cell histamine-releasing assays because non-functional as well as functional autoantibodies have been detected by Western blot and ELISA (see Table 18.3). Fig. 18.18 illustrates the overlap between: (1) autoreactivity by ASST; (2) functional autoantibodies as detected via basophil or mast cell activation assays; and (3) immunoassays ("immunoreactivity"). The most convincing evidence for an autoimmune etiology of urticaria is provided by demonstrating all three features, but some clinicians would accept a positive functional assay as providing sufficient proof of autoimmunity to guide therapies and prognosis. Because CSU patients can have increased rates of IgE sensitization to autoantigens such as thyroid peroxidase[18,93] and interleukin-24[94] and some have a very rapid response to anti-IgE antibody (e.g. omalizumab), the concept of autoallergic urticaria has been proposed.

Physical urticarias

International standards for the diagnosis of physical urticarias and definitions of challenge testing have been proposed[66]. *Symptomatic dermographism* can be tested for by stroking the skin of the back lightly with the rounded edge of a wooden spatula or a plastic device with round pegs that have different lengths (FricTest®). A calibrated instrument called a dermographometer, which is a spring-loaded stylus, the pressure of which can be adjusted to a predetermined setting, can be used to confirm the diagnosis of symptomatic dermographism (if ≤36 g/mm^2). *Delayed pressure urticaria* is confirmed if applying either a 2.5-kg weight to the thigh or back for 15 minutes (using a rod with a diameter of 1.5 cm) or a dermographometer set at 100 g/mm^2 for 70 seconds results in a palpable wheal at 30 minutes to 8 hours (usually at 6 hours).

Provocation tests for *cholinergic urticaria* include exercise to the point of sweating in an overheated environment, preferably on a treadmill or exercise bicycle, or partial immersion in a hot bath at 42°C for

Fig. 18.17 Autologous serum skin test (ASST). At 30 minutes, a red wheal response is present at the site of an intradermal injection of autologous serum, but not at that of a normal saline control. For the test to be positive, the wheal response at the serum injection site must be at least 1.5 mm greater in diameter than the control site. This criterion is a reasonably sensitive and specific screening test for functional autoantibodies as detected by the basophil release assay. Spontaneous wheals are also present at the venipuncture site and above the serum skin test.

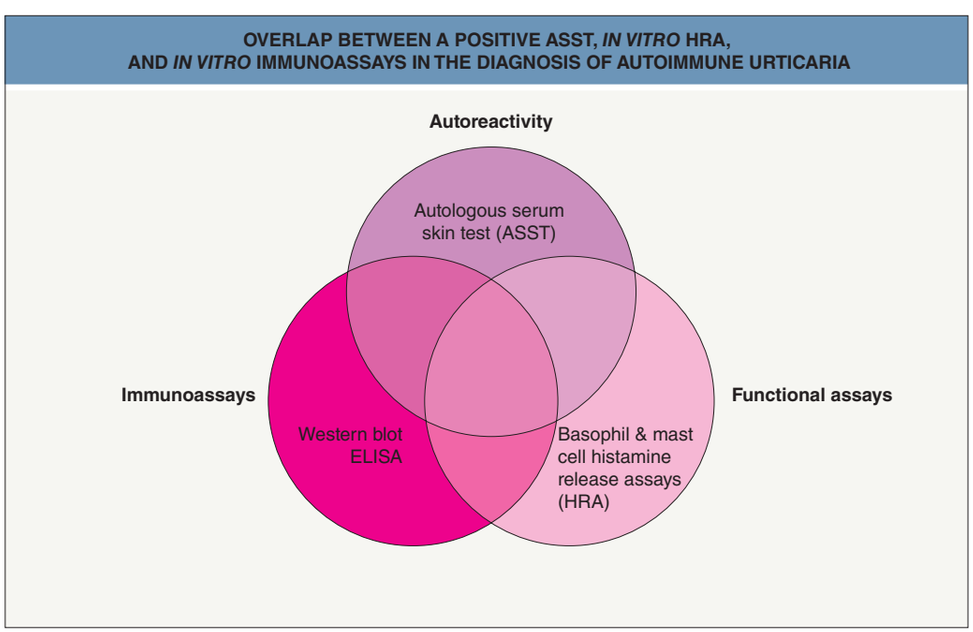

Fig. 18.18 Overlap between a positive autologous serum skin test (ASST), *in vitro* histamine release assays (HRA), and *in vitro* immunoassays in the diagnosis of autoimmune urticaria. The ASST will become increasingly difficult to perform in the future as regulations regarding blood products become more restrictive.

Downloaded for Anonymous User (n/a) at Egyptian Knowledge Bank from ClinicalKey.com by Elsevier on March 10, 2024. For personal use only. No other uses without permission. Copyright ©2024. Elsevier Inc. All rights reserved.

10 minutes. A positive hot bath test excludes exercise-induced anaphylaxis. *Cold contact urticaria* is confirmed either by the development of whealing at the site of application of a melting ice cube in a thin polyethylene bag or glove for 5 minutes (the most sensitive individuals may react after 30 seconds, with the least sensitive requiring up to 20 minutes of ice application; see Fig. 18.11) or by assessment of the critical temperature threshold by an instrument such as TempTest®.

Phototesting confirms the diagnosis of *solar urticaria*, with the development of wheals within minutes of exposure to natural or artificial radiation. The action spectra of the inducing wavelengths can be determined by narrowband monochromators (see Ch. 87). The diagnosis of *aquagenic urticaria* is made by inducing a limited number of small pruritic wheals with a large flare after a bath or shower at body temperature, or under wet gauze applied at body temperature for 20 minutes. *Heat contact urticaria* is confirmed by applying a heated cylinder (temperature increments up to 44°C) to the skin for 30 seconds to 5 minutes or assessment of the critical temperature threshold by an instrument such as TempTest®.

Urticarial vasculitis

Lesional skin biopsy is essential and should be undertaken if circled lesions consistently last >24 hours, in order to confirm the presence or absence of leukocytoclastic vasculitis histologically. The sampled lesion should have been present for 12–24 hours. Direct immunofluorescence microscopy for C3 and immunoglobulin deposits in blood vessels is generally uninformative and does not need to be performed routinely. Patients with urticarial vasculitis need a full vasculitis screen (see Ch. 24).

Angioedema without wheals

Detection of a low serum level of C4 is a very sensitive, but nonspecific, screening test for types I and II HAE and acquired C1 inh deficiency (the level is normal in nC1-INH-HAE). Measurement of the *amount* of C1 inh by immunochemical assay for type I HAE and C1 inh *function* to detect type II HAE should be performed if indicated by the history and supported by a low serum C4 level. Serum C1q levels are also reduced in acquired C1 inh deficiency (Fig. 18.19).

TREATMENT

Patients should be given advice and information on common precipitants, treatments, and prognosis. Antipruritic lotions and the avoidance of aggravating factors, including NSAIDs, may be sufficient for some, but many will need additional interventions, including systemic medications. These can be stratified into first-, second-, and third-line therapies (Fig. 18.20). The management of urticarial vasculitis is discussed in Chapter 24 and treatment of C1 inh deficiency is considered separately because its pathogenesis and therapeutic interventions differ. Patients must understand that although systemic corticosteroids may completely eliminate their lesions, recurrences often occur with tapering of the dosage and long-term use is unacceptable. In addition, H1 antihistamines and other drug combinations can nearly always control symptoms and significantly improve quality of life.

Acute, Chronic Spontaneous, and Inducible Urticarias

First-line therapies

H1 antihistamines are the mainstay of management for most patients with urticaria, although not all patients will respond and only about 40% of those attending tertiary care clinics will clear or almost clear at licensed doses. Antihistamines reduce pruritus, flatten wheals, shorten wheal duration, and reduce wheal numbers, even though they may not clear urticaria completely. It is worth discussing the relative benefit with patients who feel that "they haven't worked".

Antihistamines should be taken on a daily basis, the frequency depending on their half-life. In other words, they should not be taken only when the patient is symptomatic. As a general rule, antihistamines

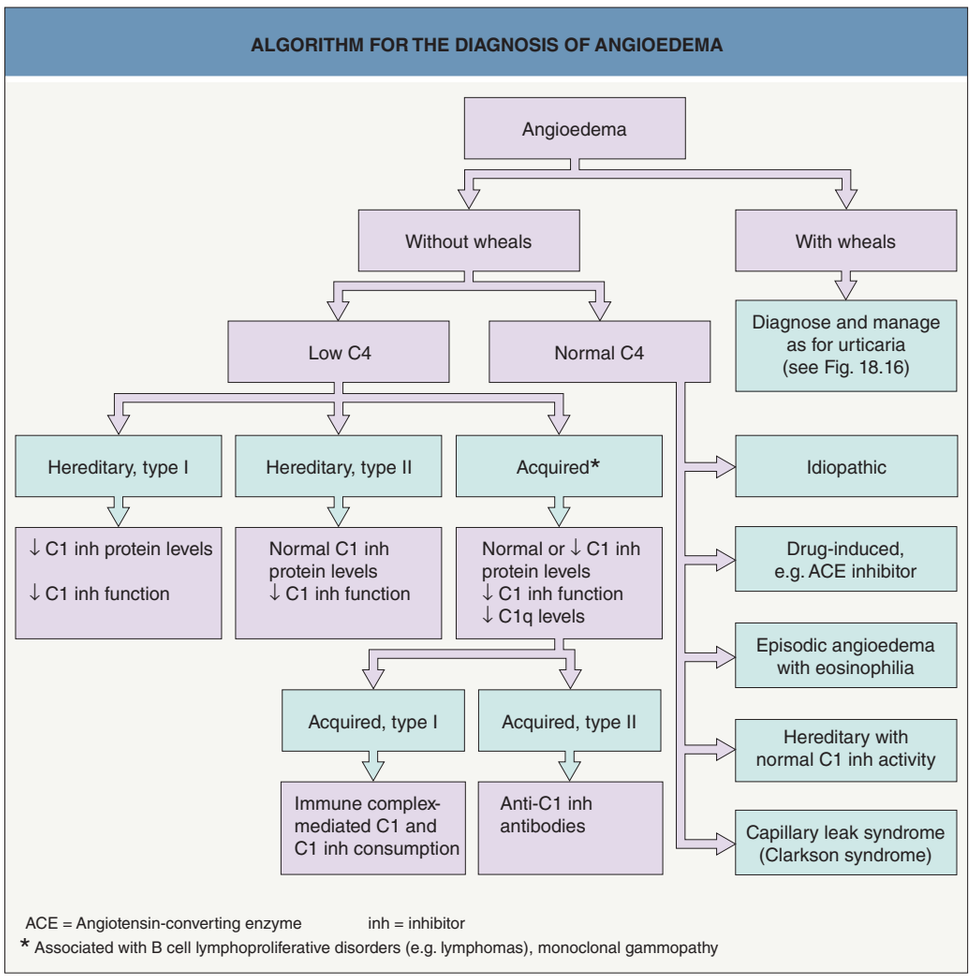

Fig. 18.19 Algorithm for the diagnosis of angioedema. Episodic angioedema with hypereosinophilia, along with weight gain and fever, is known as Gleich syndrome. There are currently 7 subgroups of HAE with normal C1 inh activity (nC1-INH-HAE, previously referred to as type III HAE); the six subgroups that have a known underlying genetic mutation are termed HAE3 to HAE8 (see Fig. 18.6), while the seventh subgroup includes those whose genetic basis is unknown.

Downloaded for Anonymous User (n/a) at Egyptian Knowledge Bank from ClinicalKey.com by Elsevier on March 10, 2024. For personal use only. No other uses without permission. Copyright ©2024. Elsevier Inc. All rights reserved.

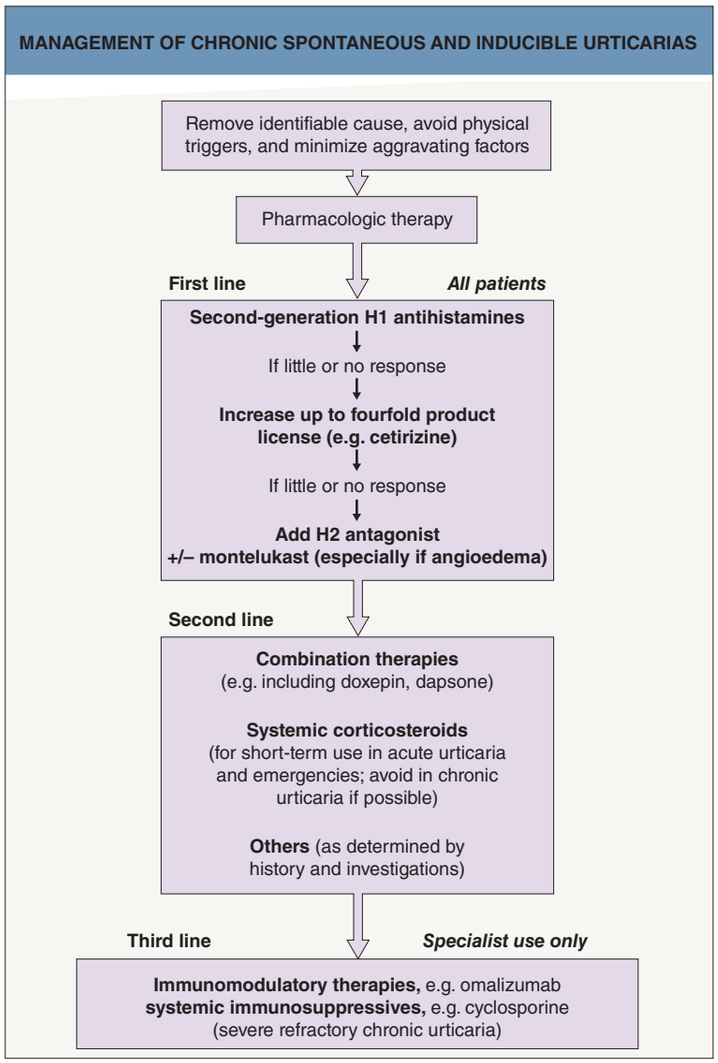

Fig. 18.20 Management of chronic spontaneous and inducible urticarias.

are safe and have few significant adverse effects. They can be grouped into first-generation (classic, sedating) antihistamines, second-generation (new generation, non- or minimally sedating) antihistamines and their derivatives, and the H2 antagonists (Table 18.5). The EAACI/GA²LEN/EDF/WAO consensus guidelines on chronic urticaria strongly recommend *against* using sedating H1 antihistamines as monotherapy[90].

Classic antihistamines

Classic antihistamines are problematic because sedation and anticholinergic side effects are often dose-limiting. However, in combination with a daytime non-sedating antihistamine, they can be taken at night if sleep is disturbed by urticaria, but the following day they may interfere with skilled tasks (e.g. operating machinery and driving) or reduce the ability to concentrate at work or school.

Second-generation antihistamines

Second-generation antihistamines are usually well tolerated, with the majority of patients requiring only once-daily oral dosing (see Table 18.5). For chronic urticaria, there is probably little distinction between the second-generation antihistamines when they are taken at the licensed dosages. A consensus paper has recommended increasing the daily dose of second-generation H1 antihistamines up to fourfold for difficult urticaria[90]. It is possible that their additional anti-allergic and anti-inflammatory properties may be clinically beneficial at these higher doses, but direct evidence for this is lacking and they do represent unlicensed dosages.

Fexofenadine is licensed for urticaria at 180 mg daily. It is the active metabolite of terfenadine but does not appear to have the potential for ventricular arrhythmias as of its parent drug. Desloratadine (an active metabolite of loratadine) and levocetirizine (the active enantiomer of cetirizine) probably offer no clinical advantage over their parent drugs at equivalent doses.

Clinically important drug interactions are infrequent, but coadministration of mizolastine with systemic erythromycin and ketoconazole is contraindicated because of concern about possible cardiac arrhythmias. Caution is also recommended with regard to other hepatic cytochrome P450 3A4 inhibitors (e.g. cimetidine) or substrates (e.g. cyclosporine; see Ch. 131), which may be used for urticaria in special circumstances.

Addition of H2 antagonists to conventional H1 antihistamines

The addition of H2 antagonists to conventional H1 antihistamines may be helpful in some patients with chronic urticaria, although clinical trial evidence for combining H1 antihistamines and H2 antagonists is poor and not all authorities recommend this therapeutic approach. H2 antagonists have no effect on histamine-induced pruritus and should not be used as monotherapy. Nizatidine and famotidine have similar properties to ranitidine (currently unavailable) but have not been evaluated in clinical trials for chronic urticaria. They are preferable to cimetidine, which may interfere with hepatic metabolism of other drugs and is weakly anti-androgenic.

Antihistamines in pregnancy

No H1 antihistamine can be advertised as being safe during pregnancy, but recent urticaria guidelines suggest loratadine and cetirizine (previously FDA category B drugs) as preferred medications, especially in the second and third trimesters. Both drugs are also compatible with breastfeeding, but hydroxyzine is contraindicated because of reports of seizures in breastfed infants (see Ch. 27). Because of its lengthy prescription record, chlorphenamine has also been used, but it should be avoided close to parturition and during breastfeeding due to potential sedative effects in the child.

Second-line therapies (targeted interventions)

Second-line therapies may be considered when urticaria does not respond well to antihistamines, but high-quality evidence to support their use is lacking. They should usually be prescribed as additive therapies (to antihistamines) rather than as alternatives. The choice of second-line drugs should be guided by specific indications, summarized in Table 18.6. Here, the management of urticaria can be influenced considerably by a full clinical assessment and the experience of the clinician. It is unusual for children to need second-line therapies, except the occasional use of prednisolone for very severe acute exacerbations of chronic urticaria. Second-line drugs should be used with considerable care in pregnancy, and only after the risks have been carefully considered against the likely benefits. Non-drug interventions include diets (e.g. salicylate-free), phototherapy, and cold desensitization.

Drug therapies

Prednisone or *prednisolone* is effective for nearly all presentations of chronic urticaria, but often needs to be used at reasonably high doses (e.g. 30–50 mg daily in adults) to achieve good initial control of severe disease. It should be considered primarily for the short-term management of "crisis" urticaria and serious angioedema of the throat as a rescue medication, when, often, a single dose or several daily doses will be sufficient to re-establish control with regular full-dose antihistamines. Regular treatment with oral corticosteroids should be avoided because of the usually prolonged duration of chronic urticaria and because of their predictable long-term side effects (e.g. hypertension, weight gain, glucose intolerance, osteoporosis). Rebound is also a common problem and the long-term course of the urticaria is often not altered.

Epinephrine (adrenaline) by subcutaneous or intramuscular injection is the treatment of choice for anaphylactic shock or severe anaphylactoid reactions, whether due to an allergy, pseudoallergy, or inducible urticaria. Epinephrine may also be necessary for angioedema of the oropharynx in severe acute allergic urticaria and idiopathic angioedema, but it is rarely required for chronic urticaria and is not effective for HAE. Directing epinephrine mist from an aerosol inhaler onto mucosal angioedema may be helpful for minor episodes, but it is usually better to administer the drug intramuscularly or subcutaneously, if it is required. Side effects of epinephrine include tachycardia, anxiety, and headache. It should be used with caution in patients with hypertension, ischemic heart disease,

Downloaded for Anonymous User (n/a) at Egyptian Knowledge Bank from ClinicalKey.com by Elsevier on March 10, 2024. For personal use only. No other uses without permission. Copyright ©2024. Elsevier Inc. All rights reserved.

ANTIHISTAMINES FOR URTICARIA			
Class	**Examples**	**Plasma half-life (hours)**	**Daily adult dose***
Classic (sedating) H1 antihistamines	Chlorphenamine (1)	12–15	4 mg three times daily (up to 12 mg at night)
	Hydroxyzine (1)	7–20	10–25 mg three times daily (up to 75 mg at night)
	Diphenhydramine (2)	2.5–9	10–25 mg at night
	Doxepin† (1)	8–24	10–50 mg at night
Second-generation H1 antihistamines	Acrivastine‡ (1)	1.5	8 mg three times daily
	Cetirizine§ (1)	7–11	10 mg once daily
	Loratadine (1)	8–11	10 mg once daily
	Mizolastine¶ (1)	13	10 mg once daily
Newer second-generation H1 antihistamines	Bilastine¶	14.5	20 mg once daily
	Desloratadine (1)	27	5 mg once daily
	Fexofenadine (1)	11–15	180 mg once daily
	Levocetirizine (1)	7–10	5 mg once daily
	Rupatadine¶ (1)	6	10 mg once daily
H2 antagonists‖	Cimetidine (1)	2–3	400 mg twice daily
	Famotidine (3)	3	20 mg twice daily

*Current prescribing manuals should be consulted for details on doses in children; off-label, up to fourfold the approved doses of cetirizine and levocetirizine have been prescribed.
†Possesses potent H1 antihistaminic and H2 antagonist properties.
‡Only available in the US as a combination product with pseudoephedrine for seasonal allergic rhinitis.
¶Not available in the US.
§The active metabolite of hydroxyzine.
‖Used in combination with H1 antihistamines.

Table 18.5 Antihistamines for urticaria. A short-acting classic antihistamine may be added at night to a daily second-generation antihistamine, with or without the addition of an H2 antagonist for maximal antihistamine blockade. Key to evidence-based support: (1) prospective controlled trial; (2) retrospective study or large case series; (3) small case series or individual case reports.

SECOND-LINE MEDICATIONS FOR CHRONIC SPONTANEOUS OR PHYSICAL URTICARIA				
Generic name	**Drug class**	**Route**	**Dose**	**Special indication/associated diseases**
Prednisone or prednisolone (2)	Corticosteroid	Oral	0.5 mg/kg daily	Severe exacerbations (days only) – "rescue" treatment
Epinephrine (2)	Sympathomimetic	Subcutaneous, IM (self-administered)	300–500 mcg	Idiopathic or allergic angioedema of throat/ anaphylaxis
Montelukast (3)	Leukotriene receptor antagonist	Oral	10 mg daily	Aspirin-sensitive urticaria, delayed pressure urticaria
Colchicine (3)	Neutrophil inhibitor	Oral	0.5/0.6–1.5/1.8 mg* daily	Neutrophilic infiltrates in lesional biopsy specimens or urticarial vasculitis
Dapsone (2)	Aminosalicylates	Oral	50–100 mg daily	Neutrophilic infiltrates in lesional biopsy specimens or urticarial vasculitis
Sulfasalazine (2)	Aminosalicylates	Oral	2–4 g daily	Delayed pressure urticaria

*Available in doses of 0.5 mg or 0.6 mg, depending upon the country.

Table 18.6 Some second-line medications for chronic or physical urticaria. Current prescribing manuals should be consulted for details on dose, drug interactions, and contraindications for individual patients. The stated doses represent guidelines only. Key to evidence-based support: (1) prospective controlled trial; (2) retrospective study or large case series; (3) small case series or individual case reports. IM, intramuscular.

cerebrovascular disease, and diabetes mellitus. Coadministration of epinephrine with tricyclic antidepressants (including doxepin) and β-blockers should be avoided. For reassurance, patients who are prone to severe acute allergic urticaria and idiopathic angioedema may carry a self-administered epinephrine pen and they need to be aware of side effects, drug interactions, and potential rebound phenomenon.

Doxepin is a tricyclic antidepressant with very potent H1 antihistaminic and H2 antagonistic properties. Although it has significant sedative and anticholinergic properties, it may be valuable, especially when dosed at night in adult patients with chronic urticaria. Monitoring of serum drug levels can prove helpful as clinical studies have frequently observed subtherapeutic levels (therapeutic range for doxepin plus *N*-desmethyldoxepin = 150–250 ng/mL)[95].

Montelukast, a leukotriene receptor antagonist (see Table 130.11), may be beneficial for aspirin-sensitive chronic urticaria due to the likely involvement of leukotrienes in its pathogenesis[96]. There have been anecdotal reports of responses in refractory chronic urticaria associated with delayed pressure urticaria, but clinical experience to date has been less encouraging. It may be useful in combination with H1 antihistamines for CSU patients with angioedema[97]. Side effects are uncommon, but urticaria, angioedema, and anaphylaxis have been reported when it has been given for other indications.

Dapsone has been shown in two randomized clinical trials as well as a larger retrospective medical record review to be an effective and well-tolerated second-line therapy for patients with refractory CSU, including the idiopathic and autoimmune subtypes[98]. Its precise mechanism of action in treating CSU is unknown but is thought to be related to its inhibition of prostaglandin and leukotriene activity, disruption of neutrophil adhesion molecules, suppression of neutrophil recruitment and activation, and interference with the release or functioning of neutrophil lysosomal enzymes (see Ch. 130). Dapsone can also be considered in DPU patients who are sensitive to NSAIDs.

Downloaded for Anonymous User (n/a) at Egyptian Knowledge Bank from ClinicalKey.com by Elsevier on March 10, 2024. For personal use only. No other uses without permission. Copyright ©2024. Elsevier Inc. All rights reserved.

Sulfasalazine may be helpful for chronic urticaria when delayed pressure urticaria (DPU) symptoms predominate, providing it is tolerated. Otherwise, these patients often require systemic corticosteroids. The drug should be avoided in patients with aspirin sensitivity and as with dapsone, glucose-6-phosphate dehydrogenase (G6PD) deficiency. For both medications, a complete blood count should be monitored every 2 weeks for the first 2 months and then regularly thereafter, along with hepatic enzymes. Side effects are reviewed in Chapters 31 and 130.

Colchicine may be beneficial for chronic urticaria when predominantly neutrophilic infiltrates are seen histologically ("neutrophilic urticaria") and it is also used for urticarial vasculitis. Potential side effects are outlined in Table 130.9. Patients receiving colchicine should avoid P-glycoprotein or strong CYP3A4 inhibitors.

Anabolic steroids, such as danazol and oxandrolone, may be useful for severe cholinergic urticaria, especially in male patients, but virilizing side effects and long-term concern regarding liver toxicity are disadvantages.

Miscellaneous drug therapies described for chronic urticaria include tranexamic acid, heparin, and warfarin, but convincing evidence for their use is lacking and there are no specific situations where they appear to be better than other treatments.

Non-drug therapies

Exclusion of food additives and natural salicylates from the diet has been advocated in a number of reports. The high success rates in some series may have been due in part to the natural history of remission in chronic urticaria, as <20% of patients responding to low-pseudoallergen diets flare after double-blind, placebo-controlled challenge with individual additives[99]. Diets nevertheless remain popular with CSU patients and are worth considering when antihistamines have failed and second-line drugs are inappropriate. There is general agreement that food allergy as a cause of adult chronic urticaria is exceptional, and that investigation for relevant immediate hypersensitivity reactions should not be undertaken without a strong lead from the history.

Induction of tolerance by repeated, frequent, graduated exposures to the precipitating physical factor can be helpful for cold urticaria, solar urticaria, and heat contact urticaria. The schedule is time consuming, not all patients can be rendered tolerant, and repeated daily exposures may be necessary to maintain tolerance.

Ultraviolet therapy and photochemotherapy (PUVA) have been used for chronic urticaria, but the reported results have been inconclusive. A retrospective survey suggested that narrowband UVB (NB-UVB) phototherapy might be effective. There is limited evidence that PUVA and NB-UVB are helpful for highly symptomatic dermographism at doses usually administered for psoriasis.

Autohemotherapy with whole blood or serum has been used in ASST-positive patients but strong evidence for this intervention is lacking[100].

Third-line therapies

Omalizumab (humanized anti-IgE monoclonal antibody) has been shown to be effective for chronic spontaneous/idiopathic urticaria in large phase III studies[101,102], as well as for associated angioedema[103] and H1 antihistamine-refractory CSU[104]. The most common dosage in adults is 300 mg monthly via subcutaneous injection. High baseline IgE levels appear to be a marker for early response[105] and early relapse[106]. In retrospective studies, patients with inducible urticarias also had a high rate of complete response of symptoms[107]. After six months of therapy, omalizumab is usually discontinued, while remaining on H1 antihistamines. Recurrences do occur and longer courses may be required.

Cyclosporine (3–4 mg/kg/day for 4–8 weeks) clears or substantially benefits approximately two-thirds of patients with chronic autoimmune urticaria refractory to antihistamines[21]. However, only 25% of responders remained clear or almost clear 4–5 months after discontinuing therapy. As a result, the risk of maintaining the "impossible to wean" patient on long-term cyclosporine is potentially considerable.

Other *immunosuppressive therapies*, including methotrexate, mycophenolate mofetil, and azathioprine, may be effective in some patients with severe CSU, if cyclosporine fails. For example, *methotrexate* has been beneficial in corticosteroid-dependent chronic urticaria patients with and without evidence of functional autoantibodies[108]. *Plasmapheresis* was used successfully in some patients with chronic autoimmune urticaria in a small, open, proof-of-concept study, but it is not recommended as monotherapy because of its expense and an early relapse of the urticaria[20]. *IVIg* infusions (total of 2 g/kg over 5 days) were beneficial in the majority of chronic autoimmune urticaria patients in another small open study, with remissions in some lasting at least three years; expense and potential side effects are concerns. Potential future therapies include other anti-IgE antibodies, Bruton tyrosine kinase inhibitors, anti-KIT monoclonal antibody, and eosinophil inhibitors.

C1 Esterase Inhibitor (C1 inh) Deficiency

The treatment of C1 inh deficiency differs from that of other types of angioedema. Intravenous C1 inh concentrate or recombinant C1 inh, subcutaneous icatibant (a specific bradykinin B_2 receptor antagonist), or subcutaneous ecallantide (a kallikrein inhibitor) should be given in an emergency, as this may prove to be life-saving (see Fig. 18.6). Fresh frozen plasma may be given as an alternative to C1 inh concentrate if the latter is unavailable. Antihistamines, corticosteroids, and epinephrine are not effective in patients with C1 inh deficiency[109]. To treat an acute life-threatening attack, patients with the acquired form of C1 inh deficiency often require much higher doses of C1 inh concentrate than the 20 units/kg recommended for HAE.

C1 inh concentrate may also be given intravenously for short-term prophylaxis 1 hour before elective surgery, especially when intubation or tooth extraction is necessary. For minor surgical procedures, oral tranexamic acid (1 g four times daily in adults or 500 mg four times daily in children) for 48 hours before and after the procedure, or an increase in established maintenance doses of tranexamic acid or danazol, can be effective prophylaxis.

Longer-term prophylaxis may be necessary for patients with symptomatic recurrent angioedema or abdominal colic due to bowel edema. Subcutaneous or intravenous C1 inh (every 3–4 days), the subcutaneous kallikrein inhibitor lanadelumab (every 2 weeks), and the oral kallikrein inhibitor berotralstat (150 mg daily) are therapeutic options. As a result, the use of anabolic steroids (see above) and tranexamic acid have declined. The latter is an inhibitor of the activation of plasminogen to plasmin and is contraindicated if there is a history of thrombosis; with chronic administration, regular eye examinations and liver function tests are recommended. Because HAE may be induced or exacerbated by estrogens in oral contraceptive pills or hormone replacement therapy, they should be avoided if possible.

PROGNOSIS

Most patients with chronic urticaria can expect to benefit symptomatically from treatment, but the prognosis for complete remission has probably changed little from that in a survey done over 50 years ago, which identified that 50% of patients attending a tertiary referral center with wheals alone were clear within a year, but that 20% with wheals and angioedema continued to have symptoms 20 years from the time of onset[110]. A mean duration of disease of slightly over six years has been reported[111].

Additional figures and table on Urticarial vasulitis, available in our eBook (see inside front cover for access code).

Downloaded for Anonymous User (n/a) at Egyptian Knowledge Bank from ClinicalKey.com by Elsevier on March 10, 2024. For personal use only. No other uses without permission. Copyright ©2024. Elsevier Inc. All rights reserved.

eFig. 18.1 Urticaria. Pink edematous papules and plaques that are transient and pruritic. *Courtesy Jeffrey P. Callen, MD.*

eFig. 18.2 Urticaria. Annular and arcuate lesions.

eFig. 18.3 Urticaria – annular and arcuate lesions. Note the pallor due to edema within the lesions.

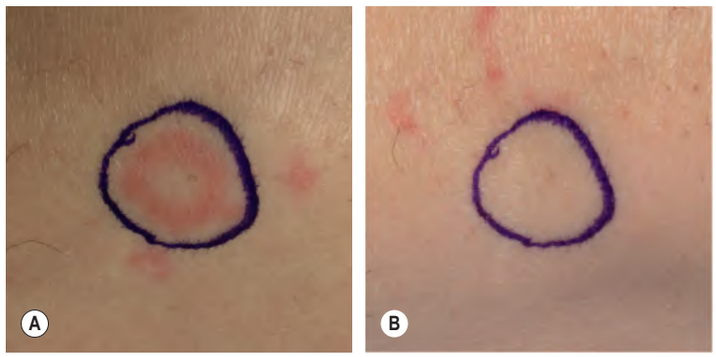

eFig. 18.4 Spontaneous urticaria. A Given the transient nature of individual lesions, circling them with ink assists in the clinical diagnosis. **B** Hours later the lesion has resolved. *Courtesy Jacob Siegel, MD.*

eFig. 18.5 Urticaria in the setting of SARS-CoV-2 infection. *Courtesy Roni P. Dodiuk-Gad, MD.*

eFig. 18.6 Yellow-colored urticaria in a patient with hyperbilirubinemia secondary to hepatic cirrhosis. The arrow denotes the elevated pink border. *Courtesy Jonathan S. Leventhal, MD.*

Downloaded for Anonymous User (n/a) at Egyptian Knowledge Bank from ClinicalKey.com by Elsevier on March 10, 2024. For personal use only. No other uses without permission. Copyright ©2024. Elsevier Inc. All rights reserved.

eFig. 18.7 Neutrophilic urticarial dermatosis in a patient with systemic lupus erythematosus. Clinically, the lesions resemble urticaria but histologically the dermal infiltrate of neutrophils distinguishes this entity. *Courtesy Nour Kibbi, MD*.

eFig. 18.8 Viral-associated trichodysplasia in a renal transplant recipient receiving tacrolimus, mycophenolate mofetil, and prednisone. Numerous skin- to pink-colored folliculocentric papules, many with central spiny excrescences, developed on the nose and cheeks. This disorder is most commonly seen in the setting of immunosuppression due to systemic calcineurin inhibitors. *Courtesy Mark Kirchhof, MD, and Sheila Au, MD*.

URTICARIAL VASCULITIS	
Epidemiology	Favors middle-aged women
Characteristics of urticarial lesions	>24 hours in duration; painful & burning sensation as well as pruritus; residual purpura as they resolve
Sites of involvement	Often occur at pressure points
Concurrent angioedema	Up to 40% of patients
Extracutaneous manifestations (% of patients affected); more common in hypocomplementemic form*	Arthralgias (50%) – transient, migratory GI involvement (20%) – abdominal pain, nausea, vomiting, diarrhea Pulmonary obstructive disease (20%) Renal (5%–10%) – proteinuria, hematuria Ocular (unusual) – conjunctivitis, episcleritis, uveitis Other (unusual) – Raynaud phenomenon, livedo reticularis, splenomegaly, lymphadenopathy, idiopathic intracranial HTN, pericardial or muscle involvement
Associated disorders	Systemic lupus erythematosus Sjögren syndrome Serum sickness Cryoglobulinemia Infections – hepatitis B or C virus, Epstein–Barr virus Rarely, solar or cold urticaria, drugs, hypergammaglobulinemia
Laboratory evaluation	CBC with differential, platelet count; ESR, CRP; LFTs, BUN, creatinine Complement assays – C3, C4, CH50; if C4 low, C1q Urinalysis If indicated, pulmonary function tests, CXR Tests for associated disorders, e.g. ANA, anti-Ro Ab
Disease course	Average of 3 years
Treatment (primarily based upon small case series and case reports; see Table 24.10)	Antihistamines for associated pruritus NSAIDs – improvement in 50% of patients Colchicine, dapsone, hydroxychloroquine, methotrexate, plasmapheresis, omalizumab in normocomplementemic form Corticosteroids ± immunosuppressants†

*Higher incidence and greater severity in patients with hypocomplementemia.
†Especially for hypocomplementemic urticarial vasculitis.

eTable 18.1 Urticarial vasculitis. In a series of 132 patients, an elevated ESR (28%), hypocomplementemia (18%), and an ANA titer >1:160 (11%) were the more common abnormalities[e1]. Ab, antibodies; ANA, anti-nuclear antibodies; BUN, blood urea nitrogen; CRP, C-reactive protein; CXR, chest X-ray; ESR, erythrocyte sedimentation rate; GI, gastrointestinal; HTN, hypertension; LFTs, liver function tests; NSAIDs, nonsteroidal anti-inflammatory drugs; PFTs, pulmonary function tests.

REFERENCE

e1. Davis MDP, Daoud MS, Kirby B, et al. Clinicopathologic correlation of hypocomplementemic and normocomplementemic urticarial vasculitis. *J Am Acad Dermatol*. 1998;38:899–905.

Downloaded for Anonymous User (n/a) at Egyptian Knowledge Bank from ClinicalKey.com by Elsevier on March 10, 2024. For personal use only. No other uses without permission. Copyright ©2024. Elsevier Inc. All rights reserved.